

Westchester
Center for
Periodontal
& Laser Therapy



January 20, 2020

To whom it may concern,

I sponsored Dr. Vasundhara Rikame to do research in 2017-2018. The project was an SEM study on the effect on dentin by different compounds including baking soda and fluoride. The study was funded to the amount of \$300 U.S. and it was through PDU Dental College Solapur. The in vitro portion of the study has already been published in 2018 and the clinical portion has been completed and is awaiting publication.

If you have any other questions about this outstanding dentist and researcher, please feel free to contact me.

Sincerely,

Robert A. Horowitz, DDS
2 Overhill Road, Suite 270
Scarsdale, NY 10583
RAHDDS@gmail.com

Dr. BIRANGANE R.S.
PRINCIPAL
P.D.U. Dental College • Solapur





Smt. Mallawabai Vaidya Memorial Charitable Dental Hospital & Research Centre, Solapur Undertaking
Pandit Deendayal Upadhyay Dental College

Recognized by Dental Council of India, New Delhi and Affiliated to M.U.H.S. Nashik
19/1, Kegaon, Solapur - 413255 (0217) 2500440, 2500441, 3243937 Fax : 2500613

Email - pdudentalcollege@rediffmail.com

Website : www.pdudentalcollege.org

No. PDUDC/PERIO-PG/KB/RESEARCH/1039/2022

Date: 20.10.2022

To,

Dr. Doshi Yogesh,

Dept. of Periodontics,

PDUDC, Solapur.


Subject: Financial aid for your project.

Reference: your Letter dated 04.10.2022

With the above mentioned subject and reference I am pleased to inform you that management has sanctioned Rs 25,000/- (TWENTY-FIVE THOUSAND RUPEES ONLY) as against financial aid to your research titled, "Evaluation of behavior of cultured osteoblasts on implant surface in presence of different graft-An in-vitro study."

The said amount will be disbursed as per your demand and submission of the receipts.




Dr. BIRANGANE R.S.
PRINCIPAL
P.D.U. Dental College, Solapur

Copy to:

1. Dr. Chole. D.G. (Executive Director)
2. Dr. Shah Mona (HOD Dept. of Periodontics)
3. Account Section.




Dr. BIRANGANE R.S.
PRINCIPAL
P.D.U. Dental College, Solapur

Date- 4/10/2022

To
Principal Sir,

PDU Dental College Solapur

Respected Sir,

This is to inform you that I Dr Yogesh Doshi along with Dr Khushboo Bansod and Staff of Dept of Periodontics is conducting an International Research Titled "Evaluation of Behavior of cultured osteoblasts on implant surface in presence of different graft- An in- vitor study" in joint Collaboration with Dr Robert Horowitz Assistant Professor Department of Periodontics and Implant Dentistry New York University And Mr. Amit Binderman CEO at KometaBio. The study protocol is attached here with all the details required.

Required material (dental implants and bone grafts) has already been provided for by Dr Horowitz and KometaBio. The study further involves conducting MTT/ XTT assay and SEM analysis of samples for which we need financial aid of approximately 500000₹. Request you to consider my proposal and provide me the financial aid for research purpose at earliest.

Credentials in publication will include acknowledgement to PDUDC college for the support provided.

Thanking you

Regards
Dr Yogesh Doshi

Yogesh Doshi

Prof. & HOD

P.D.U. Dental College, Solapur.

Inward No. 602 John E. L. 1022

Refer to Dept. Management

Refer to Person Dr. Chaitan

A.O. Principal *[Signature]*

Prof. & HOD
Dept. of Periodontics
P.D.U. Dental College
Keshavnagar, Solapur



Dr. BIRANGANE R.S.
PRINCIPAL
P.D.U. Dental College, Solapur.

TITLE:- Evaluation of behaviour of cultured osteoblasts on implant surface in presence of different grafts -An In-Vitro study.

STUDY DESIGN:-

- Osteoblasts respond to surface topography with altered morphology, proliferation, and differentiation.
- The osseointegration of oral implants is related to the early interactions between osteoblastic cells and titanium surfaces.
- Commercially available demineralized cortical allograft (Surgical Esthetics), powdered dentin and 44 implants of Straumann will be used in the study as study material.
- Particulate dentin graft will be obtained from extracted teeth.
- Periodontally compromised, non-treatable, non-carious teeth and teeth which were indicated for extraction for orthodontic purpose we will be used in the study.
- After extraction teeth will be thoroughly cleaned and soft tissue attachment will be removed using ultrasonic instrumentation.
- Teeth will be decoronated using a diamond disc. The remaining portion of the teeth will be ground using the Kometabio Smart Dentin Grinder to obtain dentin powder of particle size 200-1, 200 μm .
- Particulate dentin will be subjected to a series of chemical treatment for proper cleansing and sterilization. Powdered dentin will be washed using a cleansing solution i.e. 0.5 M of NaOH 5 minutes.
- Excess solution will be absorbed using gauze and cleansed dentin particles will then be washed in phosphate buffered saline (PBS) solution for 3 minutes.
- Half of the specimens will treated using 17% ethylene diamine tetra-acetic acid (EDTA) for 2 minutes to partially demineralize the surfaces. Demineralized dentin particles will be washed with PBS two times for 30 seconds to remove excess EDTA.
- Particulate dentin then divided into two groups according to the mineralization of the dentin: Dentin mineralized and Dentin demineralized.
- Osteoblastic cells will be grown over the surface of implants in the presence of the different graft materials.
- The samples will then be sent to the Lab for the MTT assay and field emission scanning electron microscopy.

P.D.U. Dental College, Solapur.

Inward No. _____ Date _____

Refer to Dept. _____

Refer to Person _____

A.O. _____ Principal _____



Dr. BIRANGANE R.S.
PRINCIPAL
P.D.U. Dental College, Solapur.

MATERIALS

40 Implants and bone graft provided by Dr.Horowitz

Dentin Grinders provided by Kometabio

FINANCIAL AID REQUIRED

MTT/XTT Assay -35000 rupees

Field Emission Scanning Electron Microscopy-15000 rupees

TOTAL AMOUNT – 50,000 rupees

P.D.U. Dental College, Solapur.

Invoice No.

Refer to Dept.

Refer to Page

A. O.




Dr. BIRANGANE R.S.
PRINCIPAL
P.D.U. Dental College, Solapur



Robert Horowitz

To Amit Binderman and You

Sep 5

...

t 2022-09-03 at...
B



Study protocol With Dentin..
PDF - 36 KB

3 attachments (614 KB)

- Amit - I would like to introduce you to Dr. Yogesh Doshi. He is the Principal Investigator in India for the in vitro study that you and I discussed. You will see 2 attachments that either/both of us can go over with you. The study in a nutshell is this. We want to grow and watch the spreading of cultured osteoblasts on implants that have different bone replacement grafts around them. We will start with Dentin, both partially demineralized and non-demineralized compared to demineralized freeze-dried allograft. For this round of the study, I am going to supply the implants. We are asking you to cover the cost of my purchasing the allograft, supplying the dentin grinder chambers and disposables to Dr. Doshi, ship the supplies to him and to fund the associated costs.



P.D.U. Dental College, Solapur.
Inward No. _____ Date _____
Refer to Dept _____
Refer to Person _____
A. D. _____

Dr. BIRANGANE H.S.
PRINCIPAL
P.D.U. Dental College, Solapur.

As you are well aware of what in-vitro and in-vivo studies cost, this is a mere fraction of the costs compared to other studies anywhere in the world. The results we are expecting will be quite good. In the near future, we are going to approach companies who distribute non-bioactive materials as well. This should give even more validation to all of the clinical advantages of using dentin in the periodontal and oral surgical arenas.

Please let us know if you have any questions. Thank you as always for your friendship and support.

Bobby

PS - I have copied the other stellar researchers, Drs. Khushboo and Rikame.

P.D.U. Dental College, Solapur
Inward No. _____ Date _____
Refer to Dept. _____
Refer to Person _____
A.O. _____ Principal _____



Dr. BIRANGANE R.S.
PRINCIPAL
P.D.U. Dental College, Solapur

From: Robert Horowitz <rahdds@gmail.com>
Sent: Wednesday, September 7, 2022 8:45 AM
To: Amit <amit@kometabio.com>
Cc: yogesh doshi <yogeshdoshi47@icloud.com>
Subject: Re: Dentin, Osteoblast, Implant study

I am packing up graft materials and implants to send to Amit for shipping to India.

Amit, please send me your address so we can get them out.

Thanks. This is going to be an exciting project.
Bobby

On Mon, Sep 5, 2022 at 11:50 AM Amit
<amit@kometabio.com> wrote:

Hi all,

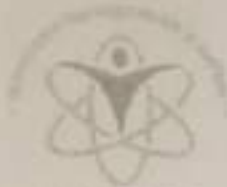It sounds like a terrific study that can be leveraged in the future as a test platform for many forms of biologics. I'll be happy to support it within the scope we discussed. I'm thinking of whether to supply the disposables for the Smart Dentin Grinder (SDG) direct, or through our distributor in Delhi – Mr. Sunil Sharma. I will speak with him and will get back to you.

Best regards,



P.D.U. Dental College, Solapur.
Forward No. Date
Refer to Dent
Refer to Person
A. O. Principal

Dr. BIRANGANE S.
PRINCIPAL
P.D.U. Dental College



MUHS

महाराष्ट्र आरोग्य विज्ञान विद्यापीठ, नाशिक

MAHARASHTRA UNIVERSITY OF HEALTH SCIENCES, NASHIK
विहारी रोड, मंगरुड, नाशिक - ४२२००४ Dindori Road, Mangrud, Nashik - 422004

Tel: (0253) 2539288

Website: <http://www.muhs.ac.in>, E-mail: urd@muhs.ac.in, muhsurd@gmail.com

डॉ. कालिदास द. चव्हाण

एम.बी.बी.एस., एम.डी. (न्यायवैद्यशास्त्र)

कुलसचिव

O. No. MUHS/URD/ १४५/2018

Dr. Kalidas D. Chavan

M.B.B.S., M.D. (Forensic Medicine)

Registrar

Date: 14/12/2018

To

Dr. Abhay S. Kulkarni,

Pandit Deendayal Upadhyay Dental

College, 19/1, Kegaon,

Dist. Solapur - 413 255.

Sub: - Approval of Research Grant of Long Term Research Grant (LTRG) (2017-18).

Dear Researcher,

With reference to above subject and your application for LTRG grant, this is to inform you that your proposal for Long Term Research Grant scheme for academic year 2017-18 has been approved for Rs. 90000/-
For Research Topic: Asymptomatic shedding of herpes simplex virus in the oral cavity. It may be noted that the sanctioned grant for the research will be released only after completion of research.

You may initiate your research work and send the project completion report within stipulated time one year. You are expected to present your interim/final research observations in the MUHS State Level Research Conference and submit the research article for publication in MUHS Health Science Review.

Research Grant will be released to the bank account of your institute after acceptance of final project report of completed research and its approval by the University scrutiny committee.

Registrar

Copy to:

The Dean/Director/Principal,
Pandit Deendayal Upadhyay Dental
College, 19/1, Kegaon,
Dist. Solapur - 413 255.



Dr. BIRANGANE R.S.
PRINCIPAL

P.D.U. Dental College - Solapur



ADC Inc.

Date : 31 January 2018

To,
The Principal,
Pandit Deendayal Upadhyay Dental College,
Solapur.

Subject : Sanction Of Research Grant

Respected Sir / Mam,

Kindly grant the research for the topic " Effect Of Ozonated Olive Oil on Oral Mucosa Lesions".

Principal Researcher : Dr Abhay Kulkarni, Reader, Oral Medicine & Radiology PDU Dental College, Solapur.

This is to certify that Rs. 10000 is sanctioned for research of topic :

Effect of Ozonated Olive Oil on oral mucosal lesions.

Dr Sudhir Dole Founder ADC Inclusive Dentozoneindia

Dr Amandeep Kaur Founder ADC Inclusive Dentozoneindia

Thank you,

DR SUDHIR DOLE, FOUNDER & CEO, ADC INCLUSIVE DNTOZONEINDIA.

+91-9930640055 | academyofdentalecareers@gmail.com

ADC Inc. Mumbai HQ Branch, Shop no. 6, Mahavir Shradha, Near Tea Trop Diagnostic Centre, Besides Hard Rock Building, Behind Ashwini Hospital, Behind Jhama Sweets, Sector 7, Kharghar, Navi Mumbai, Maharashtra 410210.



Dr. BIRANGANE R.S.
PRINCIPAL
P.D.U. Dental College - Solapur.

Date : 15th Sep 2022

To,

Dr. Abhay S. Kulkarni

PDU Dental College, Solapur


Dear Doctor

With reference to your application for research fund we are pleased to inform you that your research proposal titled "Comparative evaluation of salivary metabolites in oral cancer, Oral Submucous Fibrosis, Tobacco users without lesions and Non-Tobacco users by Gas -chromatography -MS : An analytical cross sectional study" is approved for research grant of Rs. 10,000/- to carry out research.

You are supposed to give report of utilization of research grant as you progress for research.

This is for your information and action.

With Best Regards,
Med Manor Organics


Authorized Signature




Dr. BIRANGANE R.S.
PRINCIPAL
P.D.U. Dental College, Solapur

Extracts from the Register of Copyrights



Dated : 28/12/2021


1. Registration Number : **L-109778/2021**
2. Name, address and nationality of the applicant : **DR ABHAY KULKARNI, ATHARVA OPP RAMA BIG
CINEMA TILAKNAGAR, LATUR-413512
INDIAN**
3. Nature of the applicant's interest in the copyright of the work : **OWNER**
4. Class and description of the work : **LITERARY/ DRAMATIC WORK THE CONCEPT IS
ACADEMIC AND FOCUSES ON BASICS, THE CONCEPT IS
DESIGNED TO MAKE THE BASIC CONCEPTS BETTER TO
UNDERSTAND FOR THE STUDENTS. IT ALSO HIGHLIGHTS
UNDERSTANDING BASIC TERMINOLOGIES IN SUBJECT**
5. Title of the work : **CAN VESICLE TURN INTO BULLA**
6. Language of the work : **ENGLISH**
7. Name, address and nationality of the author and if the author is deceased, date of his decease : **DR ABHAY KULKARNI, ATHARVA OPP RAMA BIG
CINEMA TILAKNAGAR, LATUR-413512
INDIAN**
8. Whether the work is published or unpublished : **PUBLISHED**
9. Year and country of first publication and name, address and nationality of the publisher : **2018 INDIA
DR ABHAY KULKARNI, ATHARVA OPP RAMA BIG
CINEMA TILAKNAGAR, LATUR-413512
INDIAN**
10. Years and countries of subsequent publications, if any, and names, addresses and nationalities of the publishers : **N.A.**
11. Names, addresses and nationalities of the owners of various rights comprising the copyright in the work and the extent of rights held by each, together with particulars of assignments and licences, if any : **DR ABHAY KULKARNI, ATHARVA OPP RAMA BIG
CINEMA TILAKNAGAR, LATUR-413512
INDIAN**
12. Names, addresses and nationalities of other persons, if any, authorised to assign or licence of rights comprising the copyright : **N.A.**
13. If the work is an 'Artistic work', the location of the original work, including name, address and nationality of the person in possession of the work. (In the case of an architectural work, the year of completion of the work should also be shown). : **N.A.**
14. If the work is an 'Artistic work' which is used or capable of being used in relation to any goods or services, the application should include a certification from the Registrar of Trade Marks in terms of the provision to Sub-Section (i) of Section 45 of the Copyright Act, 1957. : **N.A.**
15. If the work is an 'Artistic work', whether it is registered under the Designs Act 2000 if yes give details. : **N.A.**
16. If the work is an 'Artistic work', capable of being registered as a design under the Designs Act 2000, whether it has been applied to an article through an industrial process and if yes, the number of times it is reproduced. : **N.A.**
17. Remarks, if any : **THE CONCEPTS SHOULD BE IMPLEMENTED IN BOOKS
AND IN ACADEMICS FOR TEACHING AS IT HIGHLIGHTS
BASICS AND HELPS TO MAKE THE BASICS CLEAR. IT
HIGHLIGHTS OTHER CONCEPTS ALSO WHICH IS BEEN
WIDELY MISUSED.**



24047/2021-CO/L
04/10/2021
04/10/2021



**Dr. BIRANGANE R.S.
PRINCIPAL
P.D.U. Dental College, Solapur**



DEPUTY REGISTRAR OF COPYRIGHTS



Dated : 21/05/2022

- | | |
|--|--|
| 1. Registration Number | 1. L-115693/2022 |
| 2. Name, address and nationality of the applicant | 2. DR ABHAY KULKARNI, DEPT ORAL MEDICINE AND RADIOLOGY PDU DENTAL COLLEGE 19-1 KEGAON SOLAPUR-413512 INDIAN |
| 3. Nature of the applicant's interest in the copyright of the work | 3. AUTHOR |
| 4. Class and description of the work | 4. LITERARY/ DRAMATIC WORK ACADEMIC CONCEPT SHOULD BE INCLUDED IN THEORY TEACHING FOR EASY UNDERSATNING |
| 5. Title of the work | 5. DIFFERENCE OF DIAGNOSTIC BLOCK TESTING IN NEURALGIA AND PULPITIS |
| 6. Language of the work | 6. ENGLISH |
| 7. Name, address and nationality of the author and if the author is deceased, date of his decease | 7. DR ABHAY KULKARNI, DEPT ORAL MEDICINE AND RADIOLOGY PDU DENTAL COLLEGE 19-1 KEGAON SOLAPUR-413512 INDIAN |
| 8. Whether the work is published or unpublished | 8. UNPUBLISHED |
| 9. Year and country of first publication and name, address and nationality of the publisher | 9. N.A. |
| 10. Years and countries of subsequent publications, if any, and names, addresses and nationalities of the publishers | 10. N.A. |
| 11. Names, addresses and nationalities of the owners of various rights comprising the copyright in the work and the extent of rights held by each, together with particulars of assignments and licences, if any | 11. DR ABHAY KULKARNI, DEPT ORAL MEDICINE AND RADIOLOGY PDU DENTAL COLLEGE 19-1 KEGAON SOLAPUR-413512 INDIAN |
| 12. Names, addresses and nationalities of other persons, if any, authorised to assign or licence of rights comprising the copyright | 12. N.A. |
| 13. If the work is an 'Artistic work', the location of the original work, including name, address and nationality of the person in possession of the work. (In the case of an architectural work, the year of completion of the work should also be shown). | 13. N.A. |
| 14. If the work is an 'Artistic work' which is used or capable of being used in relation to any goods or services, the application should include a certification from the Registrar of Trade Marks in terms of the provision to Sub-Section (i) of Section 45 of the Copyright Act, 1957. | 14. N.A. |
| 15. If the work is an 'Artistic work', whether it is registered under the Designs Act 2000 if yes give details. | 15. N.A. |
| 16. If the work is an 'Artistic work', capable of being registered as a design under the Designs Act 2000, whether it has been applied to an article though an industrial process and if yes the number of times it is reproduced. | 16. N.A. |
| 17. Remarks, if any | |



Diary Number : 1565/2022-CO.L.
Date of Application : 25/01/2022
Date : 25/01/2022



Dr. BIRANGANE R.S.
PRINCIPAL
P.D.U. Dental College, Solapur

[Handwritten signature]

Extracts from the Register of Copyrights



Dated : 12/04/2022

- | | |
|--|--|
| 1. Registration Number | : L-114161/2022 |
| 2. Name, address and nationality of the applicant | : DR ABHAY KULKARNI, ATHARVA OPP RAMA BIG
CINEMA TILAKNAGAR, LATUR-413512
INDIAN |
| 3. Nature of the applicant's interest in the copyright of the work | : OWNER |
| 4. Class and description of the work | : LITERARY/ DRAMATIC WORK ITS AN ACADEMIC
CONCEPT. IT HIGHLIGHTS ON CLASSIFICATION OF THE
DISEASE. IT PROVIDES AN ORIENTATION TO THE
DISEASE IN ALL PERSPECTIVES OF DISEASE BASED ON
ITS PRESENTATION, SIMPLE TO UNDERSTAND. |
| 5. Title of the work | : ORAL LICHEN PLANUS AS VARIOUS DIFFERENT
ENTITIES. |
| 6. Language of the work | : ENGLISH |
| 7. Name, address and nationality of the author and if the author is deceased, date of his decease | : DR ABHAY KULKARNI, ATHARVA OPP RAMA BIG
CINEMA TILAKNAGAR, LATUR-413512
INDIAN |
| 8. Whether the work is published or unpublished | : PUBLISHED |
| 9. Year and country of first publication and name, address and nationality of the publisher | : 2018 INDIA
DR ABHAY KULKARNI, ATHARVA OPP RAMA BIG
CINEMA TILAKNAGAR, LATUR-413512
INDIAN |
| 10. Years and countries of subsequent publications, if any, and names, addresses and nationalities of the publishers | : N.A. |
| 11. Names, addresses and nationalities of the owners of various rights comprising the copyright in the work and the extent of rights held by each, together with particulars of assignments and licences, if any | : DR ABHAY KULKARNI, ATHARVA OPP RAMA BIG
CINEMA TILAKNAGAR, LATUR-413512
INDIAN |
| 12. Names, addresses and nationalities of other persons, if any, authorised to assign or licence of rights comprising the copyright | : N.A. |
| 13. If the work is an 'Artistic work', the location of the original work, including name, address and nationality of the person in possession of the work. (In the case of an architectural work, the year of completion of the work should also be shown). | : N.A. |
| 14. If the work is an 'Artistic work' which is used or capable of being used in relation to any goods or services, the application should include a certification from the Registrar of Trade Marks in terms of the provision to Sub-Section (i) of Section 45 of the Copyright Act, 1957. | : N.A. |
| 15. If the work is an 'Artistic work', whether it is registered under the Designs Act 2000 if yes give details. | : N.A. |
| 16. If the work is an 'Artistic work', capable of being registered as a design under the Designs Act 2000, whether it has been applied to an article through an industrial process and, if yes, the number of times it is reproduced. | : N.A. |
| 17. Remarks, if any | : THE CONCEPT GIVES ORIENTATION TO THE DISEASE OF
BURNING PROBLEM IN THE FIELD OF ORAL MEDICINE. IT
WILL PROBABLY GUIDE FOR FURTHER GUIDELINE FOR
TREATMENT OF UNSOLVED AND CHALLENGING ISSUE
OF DISEASE |



24036/2021-CO.L
04/10/2021
04/10/2021



Dr. BIRANGANE H.S.
PRINCIPAL
Dental College, Solapur

DEPUTY REGISTRAR OF COPYRIGHTS

Thesis abstract

Dr. Afroz Anjum

(Dept of Periodontics, Batch 2014-15)

Title:Comparative evaluation of wound healing after vestibuloplasty with diode laser and conventional techniques: A clinical and histological study.

Aim: To compare clinically and histologically wound healing after conventional surgical vestibuloplasty method and diode laser (940nm) assisted vestibuloplasty.

Material method: This study included 30 patients requiring vestibuloplasty and divided into 2 groups. Grp 1 : conventional technique; Grp 2: vestibuloplasty with diode laser. Follow up was done after surgery on 1 st day, 7 th day, 2 weeks and 3 months post operatively to compare pain using VAS and wound healing clinically and histologically.

Result: Pain significantly higher in conventional techniques at all time intervals as compared to diode laser assisted vestibuloplasty. Healing was significant in both the groups.

Conclusion: Diode laser provides better patient perception in terms of post operative pain and function a, then that obtained by scalpel technique




Dr. BIRANGANE R.S.
PRINCIPAL
D.U. Dental College Solapur

Thesis abstract

Dr. Pallavi Sonawane

(Dept of Periodontics, Batch 2014-15)

Title- Comparative evaluation of resorable guided tissue regeneration membrane to assess fibroblasts activity, bacterial activity and restorability- An in vitro study

Aim: To compare three resorable membrane (amnion, chorion, healguide) for evaluation of their fibroblastic activity, bacterial activity and restorability.

Material and Method: This study was conducted in department of microbiology. Three different sterile GTR membranes were selected for this study. Group 1 consisted of chorion, Group 2 consisted of amnion and Group 3 consisted of healguide. Bacteria to be cultured was P. Gingivalis and the enzymes to be used were collagenase and protease. The effect of barrier membranes on periodontal ligament fibroblasts cell proliferation was counted by Naubers chamber after 2, 4, 24 hrs in vitro.

Results: P value after 2 hrs is 0.18, after 4 hrs is 0.07 and after 24 hrs is 0.4 which means results of this study is not significant. P. gingivalis has the ability to adhere to all three membranes but its attachment was greater with group 3 i.e healguide when compared to other two groups group 1 showed less adherence rate compared to group 2 and group 3.

Conclusion: The study concluded that healguide showed greater P. Gingivalis adherence and chorion showed less adherence.



Dr. BIRANGANE R.S.
PRINCIPAL
P.D.U. Dental College, Solapur

Thesis abstract

Dr. Supriya Khirade

(Dept of Periodontics, Batch 2015-16)

Title: Effect of initial periodontal therapy on serum level of oxidative stress markers in patients with chronic periodontitis.

Aim: The aim of the study was to determine the effect of initial periodontal treatment on oxidative stress biomarkers in serum of patients with chronic periodontitis.

Material and Method: 60 individuals were included in this study. Group 1 consisted of 30 individuals without periodontitis and Group 2 consisted of 30 individuals with periodontitis. Plaque index, sulcus bleeding index, periodontal index, periodontal probing depth, clinical attachment level were assessed. The same operator carried out all the clinical and radiographic examination at baseline, 1 month, 3 month of the treatment. Systemic level of oxidative stress was measured by assessing serum of all the participants with the help of comet assay (single cell gel electrophoresis).

Result: There was a difference in mean values of comet assay at baseline, after 1 month and 3 months of the therapy between group 1 and group 2 which was highly significant.

Conclusion: Results of the study concluded that initial periodontal therapy was effective in improving the clinical parameters and reducing serum level.




Dr. BIRANGANE R.S.
PRINCIPAL
P.D.U. Dental College, Solapur.

Thesis abstract

Dr. Samidha Jambekar

(Dept of Periodontics, Batch 2015-16)

Title: To evaluate and compare the efficacy of tetracycline hydrochloride fibre and simvastatin gel as an adjunct to scaling and root planning in periodontitis patients and in vivo split mouth study.


Aim: The aim of this study is to compare and assess the clinical efficacy of subgingivally delivered tetracycline fibres & simvastatin gel as an adjunct to scaling root planning in treatment of periodontitis.

Material and method: The study included 20 systemically healthy patient having periodontitis and probing depth 5mm or more in atleast 3 molar teeth. These sites were divided in 3 groups, Grp1: scaling and root planning; Grp2: Simvastatin adjunct to SRP; Grp3: Tetracycline fibre adjunct to SRP.

Result: All three groups were analyzed and compared after 3 months and 6 months showed highly significant outcome in mean modified sulcular bleeding index in control group was 1.8000 respectively, in simvastatin.

Conclusion: The adjunctive use of simvastatin gel or tetracycline fibres along with scaling and root planing resulted in a significant improvement in all the clinical parameters.




Dr. BIRANGANE R.S.
PRINCIPAL
P.D.U. Dental College, Solapur

Thesis abstract

Dr. Jyoti Sirsat

(Dept of Periodontics, Batch 2017-18)

Title: A radiographic evaluation of socket preservation after tooth extraction after tooth extraction using demineralised freezed dried bone allograft and platelet rich fibrin.


Aim: The aim of the study is to radiographically evaluate the efficacy of demineralised freezed dried bone allograft and platelet rich fibrin for socket preservation.

Material and method: The study included 30 patients requiring at least 2 extraction of anterior or premolars of mandibular or maxillary arch, it included test group (demineralised freezed dried bone allograft and platelet rich fibrin) or control grp (without any grafting). All patients reported after 1 week and 3 month post extraction. The changes in the clinical and radiographic parameters were recorded.

Result: There were satisfactory radiographic findings in the test group with increased buccal plate height.

Conclusion: This study concludes that there is a good potential for the use of particulate demineralised freezed dried bone allograft associated with platelet rich fibrin for socket preservation.




DR. DILIP KANE R.S.
PRINCIPAL
P.D.U. Dental College, Solapur.

Thesis abstract

Dr. Nikita Jain

(Dept. of Periodontics, Batch 2017-18)

Title: Comparative evaluation of proliferation potential of fibroblast and osteoblast cells on demineralized dentin matrix, mineralized dentin matrix and DFDBA composite graft. An vitro study.

Aim: the aim of the study is to evaluate proliferation of fibroblast and osteoblast cells to asses the regenerative potential od demineralized dentin matrix by demineralizing dentin with ethylene di-amine tetraacetic acid (EDTA), mineralized dentin matrix and DFDBA composite graft.

Material and method: The human periodontal ligament cells were obtained from healthy human periodontal tissue. Grafts to be used were divided into 3 groups, Grp 1 : demineralizing dentin with ethylene di-amine tetraacetic acid (EDTA); Grp 2 : mineralized dentin matrix; Grp 3: demineralized bone allograft with calcium sulphate. Proliferation of cell was carried out using MTT assay method.

Result: DFDBA composite graft has shown the least favourable results overall. Demineralized dentin matrix has shown significantly positive result for both cell lines.

Conclusion : Demineralized dentin matrix caused exposure of BMPs and collagen fibres which induce bone regeneration. It may be used as potential substitute or in combination with bone grafting material for enhanced bone regeneration.



✓
Dr. BIRANGANE R.S.
PRINCIPAL
P.D.U. Dental College, Solapur


Title: Comparison of frenectomy procedures by three surgical techniques ; conventional technique; unilateral displaced pedicle flap;and bilateral displaced pedicle flap and based upon post-operative healing and patient perception of outcomes: An in-vivo study.


Aim: To compare frenectomy procedures by three surgical techniques ; conventional technique; unilateral displaced pedicle flap;and bilateral displaced pedicle flap and bilateral displaced pedicle flap based upon post-operative healing

Material and method: 30 subjects requiring frenectomy were included and divided into 3 groups grp Aa: frenectomy by con technique; Group B: unilateral displaced pedicle flap; group C: bilateral displaced pedicle flap. Patients were recalled after surgical procedure 1 day ,7days, 1 month for the healing and aesthetic outcome.

Result: On intergroup comparison of healing index at 1 month healing is better in group c than group B & A. Aesthetic outcome was more satisfactory in Group C.

Conclusion: Papillary and papilla attachment frenum shifted to negative tension test after 1 month. Healing and aesthetic were satisfactory after 1 month in bilateral displaced pedicle flap.




DR. BILKIS GANE R.S.
PRINCIPAL
P.D.U. Dental College, Solapur

Title: Evaluation of healing effects, pain perception and periodontal treatment outcomes using microsurgical open flap debridement procedure in chronic generalized periodontitis patients: A clinical study.

Aim: The aim of this study is to evaluate efficacy of the healing effects, pain perception and periodontal treatment outcomes using microsurgical open flap debridement in patients with chronic generalized periodontitis patients.

Material and method: This study included 40 sites with chronic generalized periodontitis. Patient evaluated the healing effects after 1 and 2 weeks post operatively using Early Healing Index. Evaluated pain perception after 1 and 2 weeks post operatively using Visual Analog scale. Evaluated clinical parameters when recorded at baseline, 3 and 6 months: Probing Pocket Depth; Relative mean annual attachment level (Relative clinical attachment level); Gingival bleeding index.

Result: The mean of early healing index between week 1 (2.64) & 2 (1.04) showed highly significant difference showing better healing effect and pain perception was 0.

Conclusion: The study concluded that, microsurgical open flap debridement in chronic generalized periodontitis patients provides better pain perception of the patient and healing effect, pain perception, bleeding, pocket depth, attachment level showed a significantly better outcome.




Dr. BIRANGANE R.S.
PRINCIPAL
P.D.U. Dental College, Solapur

Title: Evaluation of amniotic membrane for root coverage when used along with modified tunnel technique based on its ability of tissue regeneration: an in vivo study.

Aim: The aim of this study is to evaluate the efficacy of Amniotic Membrane for Root Coverage when used along with Modified Tunnel Technique based upon an improvement in gingival biotype and its ability of tissue regeneration

Material and Method: The study included 40 patients presenting with localized Miller's Class I and Class II gingival recession. To compare and evaluate clinical parameters when recorded at baseline, one and three months post operatively. - Recession Depth, Recession Width, Relative Mean Annual Attachment Level. To calculate the percentage of root coverage at the end of three months. To evaluate the gingival biotype recorded at baseline, one and three months post operatively- Gingival Biotype - width of keratinized gingiva, width of attached gingiva. At the end of 3 months following were recorded: - Percentage of root coverage calculated by the formula: % of root coverage = $(\text{Pre op recession depth} - \text{Post op recession depth}) \times 100$ Pre op recession depth.

Result: The overall reduction in recession width and relative mean annual attachment level was noted to be statistically significant.

Conclusion: The study concluded that amniotic membrane showed significant improvement in all the clinical parameters. There was increase in the width of Keratinized Gingiva, Width of Attached Gingiva and thickness of the gingival biotype.




Dr. BIRANGANE R.S.
PRINCIPAL
P.D.U. Dental College

Thesis abstract

Dr. Komal Gaikwad

(Dept. of Periodontics, Batch 2018-19)

Title: Comparative evaluation of serum level of 1,25 Dihydroxy - vitamin D [$25(\text{OH})_2\text{D}$] in Health, Gingivitis and Periodontitis patients.


Aim: The aim of this study was to compare serum level of 1,25 Dihydroxy -vitamin D [$1,25(\text{OH})_2\text{D}$] in Health, Gingivitis and Periodontitis patients.

Material and method: 66 patients were included in the study and divided into 3 groups consisting of 22 individuals each. Grp A: Healthy gingiva, Grp B: Gingivitis patients, Grp C: Periodontitis patients. Parameters were recorded at baseline Probing Depth, Plaque index, Attachment loss, Bleeding on Probing. Blood samples were collected from all patients. Serum 1, 25(OH) $_2$ D was analyzed using a commercially available Electro-chemiluminescence binding assay (Vitamin D total II, Cobas, Cobas e411) according to the manufacturers instructions

Result: The minimum serum level of 1, 25 Dihydroxy -vitamin D [$1, 25(\text{OH})_2\text{D}$] (ng/dl) among Group A Healthy Individuals (n=18) was 12.04 while maximum 34.00 with mean 22.6511 ± 6.76826 . The minimum serum level of 1, 25 Dihydroxy -vitamin D [$1, 25(\text{OH})_2\text{D}$] (ng/dl) among Group B Gingivitis Patients (n=20) was 08.05 while maximum 31.50 with mean 16.5490 ± 5.80823 . The minimum serum level of 1, 25 Dihydroxy -vitamin D [$1, 25(\text{OH})_2\text{D}$] (ng/dl) among Group C Periodontitis Patients (n=20) was 6.70 while maximum 28.07 with mean 12.6745 ± 5.40448 .

Conclusion: The study concluded that deficiency of serum level of 1, 25 Dihydroxy-vitamin D [$1,25(\text{OH})_2\text{D}$] is associated with periodontal diseases and this conditions can be avoided by Vitamin D3 supplements and proper oral hygiene.




Dr. BIRANGANE R.S.
PRINCIPAL
P.D.U. Dental College, Solapur

Title: Assessment of clinical and microbiological changes in patient with chronic periodontitis treated with scaling and root planing (SRP) alone and scaling and root planing (SRP) with photodynamic therapy (PDT) using 940nm diode Laser: A Split mouth randomized clinical trial.

Introduction :

Photodynamic therapy (PDT) is a treatment that uses a drug, called photosensitizer or photosensitizing agent, and a particular type of light. When Photosensitizer are exposed to a specific wavelength of light (such as laser or ultraviolet light), they produces a form of oxygen that kill nearby cells.

Aim

The aim of this study is to study to investigate clinical and microbiological changes occurring in the subjects treated with scaling and root planing (SRP) alone and scaling and root planing (SRP) with photodynamic therapy (PDT) using 940nm diode laser in chronic periodontitis patient.

Materials and Methods

A total number of 35 patients was screened, Photodynamic therapies(PDT) done on two groups using 940nm diode laser with indocyanine green dye(ICG). GI,PI,PPD,CAL,BOP also bacterial plaque sample evaluated after baseline 1month and 3 month.

Result

This clinico-microbiological study was showed statistically significant improvement in all clinical and microbiological parameters.

Conclusion

Within the limitation of study, the use of Indocyanine green dye (ICG), it is an easily available cost effective dye that is absorb infrared spectrum which allows better tissue penetration and has been found effective against periodontal pathogens even at low concentration and a significant improvement in all the clinical parameters from baseline to 3 months



K
Dr. BIRANGANE R.S.
PRINCIPAL
P.D.U. Dental College

Thesis abstract

Dr. Supriya Patil

(Dept. of Periodontics, Batch 2019-20)

Title: to compare the effect of coconut to compare the effect of coconut and sesame oil pulling practiced with chlorhexidine mouthwash in plaque induced gingivitis as an adjunct to scaling: A double blind randomized control study.

Introduction: Oil pulling is an Indian folk remedy with both systemic and dental benefits ranging from strengthening of teeth, gums and jaws, preventing decay, oral malodor and bleeding gums. However, there is limited scientific data illustrating the role of oil pulling as an adjunct to scaling and root planing. The aim of this study was to evaluate the anti-plaque effect of sesame oil pulling, cocconut oil pulling and its influence on plaque induced gingivitis as compared to chlorhexidine mouth wash.

Material and method: 60 patients with plaque induced gingivitis were treated with scaling and root planing following this randomly twenty patients performed oil pulling procedure for 14 Days (test), and twenty patients used Chlorhexidine mouthwash for 14 days (control). Plaque scores using Plaque index by Silness and Loe 1967, Gingival Index by Loe and Silness 1963 and Colony forming unit counts of bacteria were assessed at baseline, 7 days, 14 days and 21 days. Furthermore patient acceptance from either group was evaluated using a questionnaire.

Conclusion: The oil pulling therapy showed a reduction in the plaque index scores, gingival index scores, and total colony counts of aerobic microorganisms in the patients with plaque-induced gingivitis in adjunct with scaling and root planning.



✓
Dr. BIRANGANE R.S.
PRINCIPAL
P.D.U. Dental College, Solapur

Thesis abstract

Dr. Prajakta Bhabale

(Dept. of Periodontics, Batch 2019-20)

Title: To assess the knowledge and awareness regarding bidirectional relationship between periodontal diseases and general health among the medical interns from Rest of Maharashtra zone of MUHS (excluding Mumbai) - A cross-sectional study.

Introduction: Periodontal diseases are the most common inflammatory diseases affecting the oral tissues. Periodontitis, a chronic infectious and inflammatory disease of the periodontal tissue and supporting structures, has recently attracted interest as a potential risk factor for cardiovascular diseases (CVD), type 2 diabetes and also for its association with other medical conditions such as adverse pregnancy outcomes, respiratory disease, kidney disease and certain cancers

Material & Method- The questionnaire based survey conducted among 1100 medical interns of private and government medical college of Maharashtra. A self-constructed, pre-tested questionnaire was used for the survey. The questionnaire had a total of 25 questions, which were grouped into four categories. The questionnaire was sent to each participant and they were instructed to fill the questionnaire.

Result: The overall knowledge and awareness regarding bi-directional relationship between general health and periodontal diseases among medical interns was 56.3%.

Conclusion: The study concluded that medical interns required greater knowledge and awareness about impact of various systemic conditions on oral health.



Dr. BIRANGANE R.S.
PRINCIPAL
P.D.U. Dental College, Solapur

Thesis abstract

Dr. Tarannum Dhature

(Dept. of Periodontics, Batch 2020-21)

Title: To Assess Efficacy Of Diode Laser As An Adjunct To Scaling And Root Planing In The Treatment Of Type 2 Diabetes Mellitus With Chronic Periodontitis : A Split Mouth Study.

Introduction: Chronic periodontitis is a chronic inflammatory response to the accumulation of microbial plaque and calculus on the root surface of the tooth, this condition leads to breakdown of the surrounding periodontal tissues. Diabetes mellitus is a chronic metabolic disorder of the pancreas that results in marked hyperglycemia due to insulin resistance and decreased production of insulin by pancreas. It has been proposed that Diabetes mellitus 2 and Chronic Periodontitis have a two-way relationship. Although scaling and root planing produces significant clinical improvements in patients with chronic periodontitis, the complete elimination of bacterial deposits is difficult to accomplish. Laser therapy has been proposed as an adjunct treatment to conventional periodontal therapy. The use of laser in periodontal treatment improves periodontal healing and is more efficient and atraumatic technique.

Material and method : Supra gingival scaling will be done using ultra sonic scalers and Root planing will be done with the help of curettes. Under local anaesthesia full mouth scaling and root planing will be done, after scaling and root planing, laser decontamination will be done with 940 nm diode laser. Each pocket will be irradiated in 3 cycles for about 30s each. The pocket will be irrigated with normal saline. Clinical parameters will be recorded using pressure sensitive probe at baseline, 4 weeks, and 12 weeks.

- Gingival Index
- Plaque Index
- Bleeding on probing
- Clinical probing depth
- Clinical attachment level

Conclusion: From review of literature it concludes that, laser as an adjunct to scaling and root planing is an effective procedure for improving clinical parameters in diabetes mellitus patients with Chronic periodontitis.



Dr. BIRANGANE R.S.
PRINCIPAL
P.D.U. Dental College, Solapur.

Title : Evaluation of soft tissue healing and keratinized tissue formation in posterior dental extraction socket using amnion membrane and demineralized freeze dried bone graft.

Introduction: Tooth extraction may initiate various sequence of events that result in undesirable morphologic changes of alveolar ridge contour and this also affects the amount of attached gingival tissue to the alveolar bone. Preservation of ridge after tooth extraction is fundamental to the success and predictability of treatment that include conventional prosthesis and dental implants. To preserve the keratinized tissue, the amnion membrane has been considered a suitable tissue for allografting based on its low immunogenicity. It also possesses anti-inflammatory, wound protecting, and scar reducing properties.

Materials and method: This case series demonstrates the effectiveness of the amnion membrane in increasing the attached keratinized tissue over augmented extraction socket wounds and thus expanding the tissue. Patients with posterior extraction sockets were treated using the same bone graft material. The distance between the buccal and lingual flaps was measured and recorded. The amnion membrane was tucked underneath the buccal and lingual flaps by approximately 2 to 3 mm, secured with sutures, and left to heal. Postoperative visits were scheduled at 2, 4, and 12-week intervals for observation of the healing and treatment of any complications.

Conclusions: From review of literature it concludes that, the amount of bucco-lingual attached keratinized tissue was measured on the horizontal ceiling of the healed extraction socket and recorded. It showed gain in the keratinized tissue on top of the bone graft when the membrane was used.




Dr. BIRANGANE R.S.
PRINCIPAL
P.D.U. Dental College, Solapur

Title: To evaluate the effect of surgical extraction of third molar on the periodontal status of adjacent second molar: A cross sectional study

Background: The periodontal health distal of second molars (M2) is often compromised because of third molar (M3) impactions. The aim of this study was to evaluate healing and periodontal status of mandibular M2 after M3 surgical extraction.

Methods: Forty three consecutive patients with 43 asymptomatic mandibular third molar (M3) who need surgical extraction of one fully- or semi-impacted mandibular third molar will enter this study. Clinical measurements, probing pocket depth (PPD), clinical attachment level (CAL), plaque index (PI), gingival index (GI), and bleeding on probing (BOP), will be compared for M2 at baseline, 1 week, 4 weeks, 8 weeks, 12 weeks postsurgical extraction. Multiple logistic regression analysis assessed different risk factors for postoperative changes of periodontal parameters.

Conclusion: Review of literature concludes that, mandibular M3 extractions seem to improve overall periodontal health distal of M2. History of periodontitis, preoperative deep pockets and older age are independent risk factors for poorer healing and residual pockets after M3 surgical extraction.




Dr. BIRANGANE R.S.
PRINCIPAL.
P.D.U. Dental College, Solapur

Thesis abstract

Dr. Khushboo Bansod

(Dept. of Periodontics, Batch 2021-22)

Title: Comparative evaluation Of Autogenous demineralized dentin graft and Bioactive glass (Perioglass) graft in periodontal osseous defect: A Split Mouth Clinical Study.

Aim: The aim of the study is to evaluate the bone regeneration in the periodontal Osseous defect using the Bioactive glass (Perioglass) and Autogenous Demineralized dentin graft.

Material and method : A total 36 patients will be selected for this split mouth Study using autogenous demineralized dentin graft and perioglass. Under local Anesthesia after clean extraction, caries or soft tissue debris were removed from Extracted tooth. The clean and dry tooth will be then immediately grinded with a Help of coffee bean grinder. The demineralized dentin particulate of 0.5-2mm will Be immersed in basic alcohol cleanser in a sterile container to dissolve all organic Debris and bacteria for 10 minutes. Then, the particulate will be washed by sterile Phosphate buffered saline (PBS). The bacteria-free particulate dentin will be then Ready for immediate grafting into periodontal osseous defect in test group and Bioactive glass (perioglass) will be used for the control group.

Conclusion: From review of literature it concludes that, :Autogenous mineralized Dentin particulate grafted immediately after extractions should be considered as the Gold standard for socket preservation, bone augmentation in sinuses and osseous Bony defects.



✓
Dr. BIRANGANE R.S.
PRINCIPAL
P.D.U. Dental College Solapur

Title- Accuracy of three dimensional imaging as a preoperative tool in assessing the dimensions of dental furcation compared to the periodontal probing.

Aim- The aim of this study was to compare the use of periodontal probing and cone beam computed tomography (CBCT) images in assessing the dimensions of dental furcation involvement in patients with chronic generalized periodontitis.

Material and Methods- 60 patients with chronic generalized periodontitis will be included in the study. Furcation involvement will be assessed both clinically and by CBCT images. Clinical evaluation of furcation involvement will be performed using a Nabers probe by inserting the probe horizontally into the furcation to the deepest point of the defect. Clinical examinations will be performed by two trained periodontists. Both observer will examine patients in same clinical session, but separately. The examination will be performed by each examiner without the presence of another with a 30 minute interval between the examination. Patients will be further scanned using CBCT, which would be used in planning of scheduled periodontal surgery. Furcation involvement assessment through periodontal probing will be compared with data derived from CBCT images.

Conclusion- From the review of literature it concludes that application of threedimensional imaging enables a distinct and a more detailed assessment of furcation involvement than conventional approach using clinical measurements.




Dr. BIRANGANE R.S.
Dental College

Thesis abstract

Dr. Sneha Rathod

(Dept. of Periodontics, Batch 2021)

Title: A Randomized clinical study to evaluate and compare the crestal bone resorption around Implant placed with open flap technique and implant placed with flapless technique using A cone Beam computed tomography.

Aim: The aim of the study is to evaluate crestal bone changes associated with implants placed Using open flap technique and flapless technique.

Material and methods: A total of 35 implants placement following open flap and flapless Technique. The patients will be randomly assigned for the study. In open flap implant technique At the implant recipient site of the flap side a midcrestal incision is given and a full-thickness Flap is elevated, the osteotomy preparation is done, the implant is placed into the osteotomy Site and cover screw is placed, flaps are reapproximated and sutures placed. The flapless Implant technique involves the digital surgical planning and procedure is performed by soft Tissue removal using a tissue punch and placement of implant with the help of surgical guide. Follow-up examinations will be carried out at baseline, after 4th week and 12 weeks of implant Placement. Radiographic parameter will be assigned with the use of computed cone beam Tomography

Conclusion: From review of literature it concludes that, a flapless implant technique have Better clinical parameters than the flapped procedure




Dr. BIRANGANE R.S.
PRINCIPAL
P.D.U. Dental College, Solapur

Thesis abstract

Dr. Priyanka jeve

(Dept of prosthodontics, batch2020-2021)

Title- A comparative study to evaluate abutment screw loosening with internal hex parallel vs. Conical connection abutments at different torque values on cyclic loading – an in vitro study

Introduction- Common problem associated with the prosthetic application of dental implants is loosening and fracturing of screws that hold the prosthesis to the implant. It is due to insufficient tightening torque, settling effect, vibrating micro-movement, excessive bending and fatigue, inappropriate implant position, inadequate occlusal design or crown anatomy, variant of hex dimension, mild differences in fit and accuracy, tension on abutment and cylinder from ill-fitting restorations, as well as improper screw design. Screw loosening may cause implant or screw fracture, inadequate occlusal force distribution, and possible osseointegration failure. In addition, screw loosening would also lead to micro motion at the implant abutment interface while chewing. It was reported that the main factor in screw loosening was an inappropriate tightening torque

Materials and method- Implants, Internal hex parallel (ADIN dental implant systems LTD), Conical connection (Osstem co, Seoul, Korea), Abutment screws, Stainless steel model Dental surveyor, torque gauge, Metal mounting jig, Universal testing machine

Total number of 6 implants and 6 abutments, in which 3 of internal hex parallel and 3 conical connection will be used in the study. A total number of 60 abutment screws will be used considering 30 in each group of which 10 screws will be further divided according to different torque values 10Ncm, 20Ncm, 30Ncm each.

Conclusion- from review of literature it concludes that, Internal hex parallel connection shows more screw loosening than the conical connection, and Increase in torque value will increase the screw loosening.




Dr. BIRANGANE R.S.
PRINCIPAL
P.D.U. Dental College, Solapur

Aim- study to evaluate the accuracy of different implant level impression techniques against scan body impression.

Material method-

This In-vitro study was carried out to compare and evaluate the positional accuracy of implant level impressions obtained from Conventional open tray and closed tray techniques with Digital scan body impression. In Group 1-Metal master model was fabricated to act as a reference model. In Group 2 -15 conventional open tray impressions were made. In Group 3-15 closed tray impressions were made. In Group 4-15 digital impressions were made. 15 open tray and 15 closed tray models were prepared with dental stone. for digital group the two scan bodies were attached to master model and scanning was done with TRIOS 3Shape IOS and 15 digital impressions were obtained. Interimplant distance of stone models was measured with CMM machine. for digital impression .STL file of whole digital scan was prepared and analyzed using CAD software. Interimplant distance of four groups were statistically analyzed.

Results- The study shows that there is statistically significant difference in positional accuracy of conventional open tray ,closed tray Implant Impression and digital scan body impression technique.

Conclusion- A conventional Open tray implant impression technique showed less deviation from reference model measurements. It was the most accurate when compared with the other two techniques. Digital implant impressions with the TRIOS 3Shape IOS had the less accuracy when compared to conventional Open tray implant impression techniques.



Dr. BIRANGANE R.S.
PRINCIPAL
P.D.U. Dental College Solapur.

Aim- The aim of this in-vitro study was to evaluate and compare the accuracy of post space obtained from intraoral scanner, silicon impression, and direct pattern resin.

Material and method- Ten freshly extracted human Maxillary Central Incisor were collected and mounted with the tooth on either side to simulate the clinical situation in self-curing polymethyl methacrylate resin to the level of the cemento-enamel junction. Post space was prepared keeping 5mm gutta percha apically. 10 impression were made of total 6 groups

Group 1 (Control group)- Post space length was measured from the coronal most portion of the decoronated tooth using k file and digital vernier caliper.

Group 2 (Indirect impression technique)- Impressions were made with customized light-cured resin tray, coated with tray adhesive and was loaded with the putty and light-bodied material.

Group 3 (Direct impression technique)- Post and core pattern was made from prefabricated acrylic resin post along with pattern resin. Group 4 (Intraoral scanner)- the intra-oral scanner was positioned at an angle of 45° with the sample and successive images were obtained by moving the scanner to the mesial, lingual, distal, buccal, and occlusal sides, respectively, starting from the centre of the corresponding root canal. The intra-oral scanner was positioned at an angle of 45° with the sample and successive images were obtained by moving the scanner to the mesial, lingual, distal, buccal, and occlusal sides, respectively, starting from the centre of the corresponding root canal.

Group 5 (Zirconia post)- wax patterns were fabricated from the cast obtained from indirect impression technique. The pattern was then scanned through EXO CAD software and then milled into zirconium oxide post.

Group 6 (Cast metal post)- Indirect impressions obtained from group II were poured in type IV gypsum product in order to obtain a cast. Cast metal post pattern was made with type II inlay wax. All cast metal posts were fabricated in the dental laboratory using the lost wax technique.

Result- It was done to evaluate the difference in the length by using Tukey's Post Hoc test. Highest difference was observed between the mean values of post space length (group I) and the length of post space obtained by digital technique (group IV). Least difference was observed between the mean values of post space length (group I) and post space length obtained by using direct technique (group III) and Graph 1). Based on values obtained from different techniques, there was statistical significant difference between group I and group IV, group I and group V and group I and VI. However, there was no statistically significant difference seen between group I and group II also group I and group III.

Conclusion- Within the limitations of the study following conclusion can be drawn

1. Impression of post space obtained from the intraoral scanner was less accurate as compared to direct impression technique and indirect impression technique and there was a statistical difference between the length measured from the impression obtained from intraoral scanner and actual length of the post space and other traditional impression techniques (direct and indirect impression technique).
2. Cast metal post and zirconia post fabricated using indirect technique produced significantly shorter posts when compared with prepared post space length.
3. There was no significant difference between cast post and zirconia post in terms of length.
4. Mesiodistal dimensions obtained from prepared post space and those obtained from direct, indirect, and digital impression techniques had no significant difference whereas a significant difference was noticed between the mesiodistal dimension of the prepared post space and those obtained from cast metal post and zirconia post.



Dr. BIRANGANE R.S.
PRINCIPAL
P.D.U. Dental College, Solapur

Abstract

Background- Prosthodontics is a branch of dentistry which focuses on providing rehabilitative care for the damaged hard and soft tissues of oral cavity. The modalities associated with it are targeted towards providing a treatment substitute to the natural dentition which has been lost because of various reasons. The replacement can either be removable & fixed complete arch prosthesis or partial replacement. The replacement by dental implants has evolved as a result of advancement in science in dentistry.

Aim- The aim of this study was to evaluate positional accuracy of implant analog position in conventional dental stone cast obtained from splinted impression post impression, non-splinted impression post impression versus 3-D printed polymer models using a co-ordinated measuring machine.

Materials and methods: This study was conducted to evaluate the positional accuracy of implant analog on stone cast obtained from splinted and non-splinted impression technique and polymer models obtained from 3D printed Stereolithography technique. 1 metal master model was fabricated simulating the maxillary edentulous arch. 7 casts were made by splinted open tray impression technique and 7 by non-splinted open tray impression technique respectively. 7 polymer models were printed by scanning and 3-D printing technology.

Result: The accuracy was highest for 3D polymer model followed by splinted impression technique and then non-splinted impression technique on x-axis. While on y-axis, 3D polymer model displayed the highest accuracy which was followed by non-splinted technique and splinted technique. Though the x axis showed more accuracy with splinted and y with non-splinted but in both the axis the difference between splinted and non-splinted was not statistically significant. Both the techniques showed comparable deviation from the accurate position.

Conclusion: Within the limitations of the study, it can be concluded that the positional accuracy of implant was highest for 3D polymer model followed by splinted impression technique and non-splinted impression technique on x-axis. While on y-axis, 3D polymer model displayed the highest accuracy which was followed by non-splinted technique and splinted technique. Though the x axis showed more accuracy with splinted and y with non-splinted but in both the axis the difference between splinted and non-splinted was not statistically significant.



Dr. Birangane R.S.
Dr. BIRANGANE R.S.
PRINCIPAL
P.D.U. Dental College, Solapur

Thesis Abstract

Dr. Amer Mohsin Badaam

(Dept of Prosthodontics, Batch 2017-2020)

Title- A comparative study to evaluate the effect of open and closed tray impression technique on the vertical misfit of a screw retained, three unit implant supported fixed partial denture using polyether as impression material – an in vitro study.

Aim: The aim of this study was to evaluate the effect of different techniques used to take an impression on the vertical misfit of implant-supported, screw-retained, three-unit FDP.

Materials and Methods: The principle of this study was evaluation of the vertical misfit between the CAD-CAM fabricated master framework and the non engaging standard abutments screwed with the torque of 25 Ncm on metal master model under the optical light microscope. Ten casts were fabricated by open tray impression technique and closed tray impression technique respectively. The impression material used was polyether. The marginal gap in the framework at three points (buccal, lingual, and distal) was measured using an optical microscope with $\times 500$.

Results: Comparison of the vertical misfit between the open tray and closed tray groups. When group one (open tray) was compared with group two (closed tray) group-1 showed lower vertical misfit than the group 2 [group-1 < group-2].

Conclusion: Within the limitations of this study, the following conclusions can be drawn: A higher marginal accuracy was obtained using polyether impression material by open tray impression as compared to closed tray impression.

Key Words: Dental implant, impression, open/closed-tray technique, vertical misfit.




Dr. BIRANGANE R.S.
PRINCIPAL
P.D.U. Dental College, Solapur

Dr. Nakul Ware

(Dept. of prosthodontics , batch 2017)

"A COMPARATIVE EVALUATION OF DIMENSIONAL ACCURACY BETWEEN OPEN-TRAY AND CLOSED-TRAY IMPLANT IMPRESSION TECHNIQUE IN 0 DEGREE, 10 DEGREE AND 17 DEGREE ANGLED IMPLANTS – AN IN VITRO STUDY."

Aim of the Study

To compare the dimensional accuracy between open tray and closed tray impression technique with 0 , 10, 17 degree angled implants using polyether impression material.

Materials

1. Implant fixture with internal hex- (4.2D×10L Adin Co.)
2. Implant analog – (Adin Co.)
3. Open-tray impression coping (Adin Co.)
4. Closed-tray impression coping (Adin Co.)
5. Hex-driver (Adin Co.)
6. Polyether impression material – (Impregum 3M ESPE)
7. Visible light cure base plate (Profibase, Voco-Germany)
8. Dental stone, high strength (type IV) – (ULTRAROCK, KALABHAI KARSON, MUMBAI, INDIA)
9. Cyanoacrylate – (Fevikwik)
10. Tray adhesive (Medicept)

Method

A steel model, of dimensions 4 cm diameter and 1.5 cm height, was fabricated to be used as a metal master model. A 09 models of each Open Tray and Closed Tray are made from visible light cure base plate. A bridge-type computerized coordinate measuring machine was used for making measurements. According to the manufacturer, the accuracy of the CMM was 0.0018 mm for the X, Y, and Z axes.

Result



Dr. BIRANGANE R.S.
PRINCIPAL
P.D.U. Dental College, Solapur

This study was performed to compare the dimensional accuracy between open-tray and closed-tray implant impression technique in 0 degree, 10 degree and 17 degree angled implants.

Total 8 impressions were made that were divided into two Groups of 4 samples each.

Group 1: Four Casts obtained from open tray impression technique.

Group 2: Four Casts obtained from closed tray impression technique.

The casts were analyzed by co-ordinating measuring machine devices in three dimensions (x, y and z) for evaluating the position of implants and dimensional changes. Therefore, they were fixed on mounting plate using a vise for further measurement. A fine tip stylus was then adopted to record the multi-axial coordinators (x, y and z) on the upper surface of internal hex implant.

The mean dimensional changes in open tray impression technique at 0degree, 10degree and 17degree were found to be 0.737, 0.399 and 0.448 in X-axis, 0.289, 0.325 and 0.382 in Y-axis and 0.00 in Z-axis. The mean dimensional changes in closed tray impression technique at 0degree, 10degree and 17degree were found to be 0.052, 0.355 and 0.339 in X-axis, 0.269, 0.283 and 0.479 in Y-axis respectively and 0.00 in Z-axis.

The mean difference between open tray impression technique and master model at 0 degree were 0.07 at X-axis, 0.28 at Y-axis and 0.00 at Z-axis. At 10 degrees, it was 0.39 at X-axis, 0.32 at Y-axis and 0.00 at Z-axis and at 17 degree, it was 0.44 at X-axis, 0.38 at Y-axis and 0.00 at Z-axis. The p value with 0 degree is 0.04 (p value < 0.05), it shows that there is a statistically significant difference between dimensional accuracy of models obtained from open tray impression technique as compared to master model at 0 degree.

The mean difference between closed tray impression technique and master model at 0 degree were 0.05 at X-axis, 0.26 at Y-axis and 0.00 at Z-axis. At 10 degrees, it was 0.35 at X-axis, 0.28 at Y-axis and 0.00 at Z-axis and at 17 degree, it was 0.33 at X-axis, 0.47 at Y-axis and 0.00 at Z-axis. As p-value > 0.05 it suggests that there is no significant difference between models obtained from closed tray impression technique and master model.

Conclusion

The present study was done with aim to evaluate the dimensional accuracy between open-tray and closed-tray implant impression technique in 0 degree, 10 degree and 17 degree angled implants.



Dr. BIRANGANE R.S.
PRINCIPAL
P.D.U. Dental College, Solapur

Dimensional accuracy of closed tray and open tray impressions was determined using co-ordinating measuring machine. The results obtained did not show any statistically significant difference when compared to master model in x, y, z plane indicating that closed tray technique accurately replicates the dimensions in angled implants.




Dr. BIRANGANE R.S.
PRINCIPAL
P.D.U. Dental College, Solapur

TITLE - Comparative evaluation of influence of water sorption on flexural strength of three commercially available injection molded thermoplastic denture base resins -An in vitro study."

AIM - To evaluate the influence of water sorption on flexural strength of injection molded thermoplastic denture base resins.

MATERIAL AND METHOD - 80 specimens were prepared. Based on the type of acrylic resin used, the specimens were divided into 8 groups with 10 specimens each. Each group was subjected to flexural strength evaluation. The method used in this study is described under following sequential steps-

Step 1 - Fabrication of machine milled metal dies. Step 2 - Grouping of samples.

Step 3 - Preparation of samples. Step 4 - Dimensions of samples verification.

Step 5 - Storage of samples. Step 6 - Measurement of water sorption of samples.

RESULTS - ANOVA revealed significant differences among the various denture base materials for the ultimate flexural strength, FS-PL and elastic modulus ($P < 0.05$). All of the injection moulded thermoplastic resins had a significantly lower FS-PL than the denture base control, ProBase (PMMA) ($P < 0.05$).

CONCLUSION - Water sorption significantly decreased the flexural strength, flexural strength at proportional limit ,and elastic modulus of all the injection moulded as well as conventional heat cure denture base resin . All of the injection moulded thermoplastic resins had significantly lower flexural strength, flexural strength at proportional limit, lower elastic modulus, than the conventional heat-polymerized acrylic resin.



Dr. BIRANGANE R.S.
PRINCIPAL
P.D.U. Dental College, Solapur

Title-"COMPARATIVE EVALUATION OF SHEAR BOND STRENGTH BETWEEN ACRYLIC TEETH AND DENTURE BASE MATERIAL AFTER FOUR DIFFERENT TYPES OF SURFACE TREATMENT: AN INVITRO STUDY"

AIM:

Aim of this study is to evaluate the bond strength between acrylic teeth and denture base material after four different types of surface treatment.

Materials and method- Heat cure denture base resin- Probase, Acrylic teeth- Acryrock, Dental plaster- White gold, Dental stone- Gold stone, Separating media- Acralyn- h, Sand papers of grit- 220, Bonding agent- methyl methacrylate based (superbond), Coupling agent- silane coupling agent(RelyXs-3M ESPE)

The total sample size for the study will be 80 with each group comprising 20 specimens. The ridge lap surface of all the acrylic molar teeth will be planed using acrylic trimming metal bur. They will be further evenly treated using 220 grit dry and wet sand paper. A standardized tapered metallic cylinder with flat end will be fabricated. An openable lid will be fabricated on the narrow end of the cylinder. A separating media in the form of petroleum jelly is applied on the inner surface of the metallic cylinder and the molten wax will be poured. The prepared tooth will be placed and sealed on to the wax at the cervical area. Wax will be allowed to cool and the tooth with the wax assembly will be separated from the cylinder. Then assembly will be flaked by two pour technique using dental stone to make the mold. After de-waxing, four different types of surface treatment will be done.

RESULT & Conclusion- The shear bond strength after four different types of surface treatment i.e. treating with sand paper, coupling agent, cyanoacrylate and methyl methacrylate based bonding agent were evaluated and compared. Within the limitations of this study, following conclusions were drawn:
1. Methyl methacrylate based bonding agent had highest bond strength when used as surface treatment of bonding surface. 2. Silane coupling agent increased the bond strength significantly compared to control group. 3. Cyanoacrylate application for surface treatment had least shear bond strength, lesser than the control group as it acted as interference instead acting as bonding agent at the inter



Dr. BIRANGANE R.S.
PRINCIPAL
P.D.U. Dental Colls. Solapur

Title-

"A COMPARITIVE STUDY TO EVALUATE THE RETENTION OF CEMENT RETAINED IMPLANT PROSTHESES WITH SCREW ACCESS CHANNEL AND WITHOUT SCREW ACCESS CHANNEL"-AN IN VITRO STUDY

Aim & Objectives-

- To evaluate the retention of conventional cement retained implant supported crowns.
- To evaluate the retention of the cement retained implant supported crowns with a screw access channel.
- To evaluate whether surface treatment of the abutment has any additional effect on retention of cement retained implant supported crowns with screw access channel.
- To evaluate the intercomparison of above three groups.

Material & Method- This study involves 30 Co-Cr copings divided into three groups.
Group 1- Ten cement retained copings on standard abutment (control group)
Group 2- Ten cement retained copings with screw access channel on standard abutment (study group)
Group 3- Ten cement retained copings with screw access channel on standard abutment, sand blasted with 50µm Alumina 1mm above the finish line (Study group),
All the copings were cemented with with RelyX™ U200 and each specimen was subjected to tensile bond strength test using universal testing machine at a cross head speed of 5mm/min. The force at which the bond failure occurred was recorded in Newtons

Result- the kolomogorov and smirnov test for 3 groups the P value obtained >0.1 . the one way ANOVA the F value 2.63 and P value was 0.09.

Conclusion-the placement of screw access channel in implant supported cement retained crown compared to conventional cement retained crown doesnt have any effect on tensile bond strength,when definitive cement relayX U200 with implant abutment of 2mm of collar height was used.tensile bond strength of crown was not significantly increased by surface treatment.



Dr. BIRANGANE R.S.
PRINCIPAL
P.D.U. Dental College, Solapur

THESIS ABSTRACT

Dr. Rashmi Channe

(dept of oral medicine and radiology batch 2016-19)

GENDER DETERMINATION BY PANORAMIC RADIOGRAPH (OPG) ANALYSIS OF MENTAL FORAMEN IN WESTERN MAHARASHTRA POPULATION: - A RETROSPECTIVE STUDY

Aim : To determine the gender using mental foramen as landmark on a panoramic radiograph in western Maharashtra population: -A Radiographic study.

Objectives: 1. To measure the distance between the superior margin of mental foramen to lower border of mandible on both side (S-L) and the distance between inferior margin of mental foramen to lower border of mandible on both side(I-L).

2. To compare the S-L and I-L between right and left side in males and females.

3. To utilize above measurements for gender determination.

Materials: 150 digital panoramic radiographs of dentulous patients (75 Male, 75 Female). Radiographs taken with CareStream 8000c and with the standard parameters only will be considered for the study. CareStream Dental Imaging Software for The system used for the analysis of digital radiographs was Lenovo G80 laptop, with 15.6 inch LED backlit LCD, having a resolution of 1366 x 768 pixels. Logitech B60 mouse was used. A silent room with subdued lighting was used for the interpretation of the radiographs.

Methods: Total sample of 150 patients (18 to 50 years age group) digital OPG will be selected after considering all the exclusion criteria and falling under inclusion criteria. Mental foramen were identified clearly and marked. The tangent were be drawn through the superior and inferior margins of the mental foramen and perpendicular lines drawn from tangent to the lower border of the mandible. Digital Software will used to measure the distance from superior margin of mental foramen to lower border of mandible (S-L) and inferior margin of mental foramen to the lower border of mandible (IL) bilaterally. These measurements was done on the right and left sides of the mandible. The measurements were tabulated and analyzed for mean value in males and females on both the right and left sides. The data so obtained were analyzed statistically for gender determination.

Result : The present study undertaken for radiographic determination of mental foramen on panoramic radiograph for gender determination. The measurements were taken in a step wise manner. First, we drew 2 tangents from superior and inferior margin of mental foramen. Second, lines were drawn from superior and inferior margins of mental foramen to inferior border of mandible on both sides and then measured digitally on digital panoramic radiographs using CareStream Dental Imaging Software. The comparison of S-L between males and females



Dr. BIRANGANE K.D.
PRINCIPAL
Solapur

showed a high significant difference on both the right and the left sides. The comparison of I-L between males and females suggested a highly significant difference on both right and left sides. The comparison of I-L between males and females showed a high significant difference on both the right and the left sides.

Conclusion: To conclude the present study, the following parameter such as superior margin of mental foramen to inferior border, inferior margin of mental foramen to inferior border showed statistically significant difference. We found that mental foramen measurements using panoramic radiographs were reliable for gender determination. This method can be applied in mass disaster where the fragments of Mandible are available

Dr. Abdullah Zakaria Kazi

(dept of oral medicine and radiology batch 2016-19)

Evaluation of the visibility and the course of the mandibular incisive canal and the position of lingual foramen using cone beam computed tomography- a retrospective study

Aims:

1. To assess the visibility and the course of the mandibular incisive canal using cone-beam computed tomography (CBCT).
2. To assess the visibility and the location of the mandibular lingual foramen using cone-beam computed tomography (CBCT).

Objectives:

1. To assess the average position and course of incisive canal with respect to the inferior border, buccal and lingual wall of mandible.
2. To assess the average position of lingual foramen with respect to the inferior border of mandible


Materials and Methods

The material for this study consisted of 70 CBCT examinations of the mandible, which were recorded using CareStream 9300 System. CBCT scans of interforaminal region of mandible, which may be dentulous (dentate) or edentulous.

Subjects of age group 18-80 years old were assessed.

Results-

This study sought to establish average measurements that may be useful to clinicians as guidelines for the location of the MLF and MIC. The number of MLF present was highly variable in each scan and their number ranged from 1-5. In all the scans studied, MLF was present in the midline with slight variation in few cases (ranged between 4 mm on the right to 4 mm on the left of midline). It was found that the MLF opens into canals which run from the lingual cortex towards the buccal cortex. The average number of MLF seen was 2.33, and out of 70 scans 61 showed at least two MLFs and all the scans showed at least one MLF. From the two most commonly seen MLF, one was positioned above the genial tubercles and the other was



Dr. BIKASH
PRINCIPAL
P.D.U. Dental College, Solapur.

positioned below it. On an average, the superior most MLF was 13.85 mm from the inferior border of the mandible.

Conclusion

The high prevalence and wide variability of the anatomic location, course and extent of the incisive canal in this study strongly highlights the importance of knowledge regarding this anatomical entity and the need for its evaluation prior to surgical procedures in the implant dentistry. It is important that professionals identify and protect this important neurovascular bundle when planning procedures involving the interforaminal region to avoid the possible complications which range from transient paresthesia to life threatening hemorrhages.

Dr. Vasundhara Bandagi

(dept of oral medicine and radiology batch 2017-20)

Evaluation of association between the sublingual varices and hypertension.

Aim: The aim of this study was to assess the relation between sublingual varices and hypertension.

Materials and Method: The study was conducted in the Department of Oral Medicine and Radiology. Approval by the Ethical Committee was obtained before commencement of the study. An informed consent was taken from the patients. A specially designed case record form [Annexure] was used to collect the required information from each patient. This was a prospective observational study conducted in the Department of Oral Medicine and Radiology. Study conducted on 600 patients those were divided into two groups

1. **Group 1-** 400 (No history of hypertension- No HTN group)
2. **Group 2-** 200 (with History of hypertension- HTN group)

Sample size was calculated using the formula

$$n = Z\alpha^2 pq / L^2$$

Where n= sample size

point on normal distribution with 95% confidence level)

p= Prevalence of sublingual varices= 25% (A GOI – WHO Collaborative Programme 2006-2007) L= allowable error which is equal to 10% of p



DR. BIRANGANE R.S.
PRINCIPAL
P.D.U. Dental College Solapur

Results: Nearly half of the study population belonged to the age group 60-79 years with the number of 220 (55%) and 95 (47.5%) in No HTN and in HTN group respectively. Total 219 males in No HTN group and 99 in HTN in group was seen. Female proportion in No HTN group and in HTN was 181 and 101 respectively. In age and gender wise distribution of the patients, proportions of females were considerably higher than that of males in 40-59 age groups and 60-79 age groups. In 80-99 proportion of males were higher than that of female.

Conclusion:

Tongue is known to be a mirror of the oral and general health. It is an important diagnostic tool that can be used to examine the physiological, functional and pathological changes of the internal organs. In the present study I concluded that the presence of sublingual varices is the initial sign/ or suspicious of hypertension which gives dentist a clue for further investigation thereby avoiding subsequent unwanted general consequences and care to be taken during dental procedure.

Dr. Shruti Sajjan Wadne


(dept of oral medicine and radiology batch 2018-2021)

Morphometric evaluation and comparison of soft palate in individuals with and without oral submucous fibrosis: a digital cephalometric study

Aim: The aim of this study was to evaluate and compare the morphology of soft palate in individuals with and without OSMF, using digital lateral cephalogram.

Materials and method: The study was conducted in the Department of Oral Medicine and Radiology. Approval by the Ethical Committee was obtained before commencement of the study. An informed consent was taken from the patients. A specially designed case record form [Annexure] was used to collect the required information from each patient. This was a Descriptive Cross- sectional Study conducted in the Department of Oral Medicine and Radiology.




DR. BIRANGA
PRINCIPAL
P.D.U. Dental College, Solapur.

Study was conducted on 90 study patients were divided into 3 groups:

1. Group I - 30 individuals with established OSMF group (study group 1)

2. Group II - 30 individuals with Habit only (study group 2)

3. Group III - 30 individuals with no habit and/ or OSMF group (control group)

Sample size was calculated using the formula

$$n = Z^2 pq / L^2$$

Where n= sample size

Z α 2 = point on normal distribution with 95% confidence level)

p = Prevalence

L = allowable error which is equal to 10% of p

Results: In study group-1, type-1, type-2, type-3, type-5, type-6 soft palate variant was most commonly found, of which type-6 variant has the highest percentage. In study group-2, type-1, type-2, type-3, type-5, type-6 were most commonly found which indicates that alterations in morphology of soft palate even before the development of Oral Submucous Fibrosis. In both the study groups type-4 variant of soft was not found. In control group, type-2 variant of soft palate was most commonly found.

Conclusion: The present study highlighted various morphological appearances of soft palate and comparison with habit and OSMF group on cephalogram. Cephalometry can be efficiently used to assess the morphology of soft palate and the morphology of soft palate was altered in individuals with habit even before development of OSMF. Thickness of soft palate was affected more as compared to its length. As the OSMF progresses the type of soft palate changes from type-1 to type-3 & type-6. A gradual reduction in A-P length and increase in S-I length was observed, suggesting that soft palate becomes shorter and thicker with advancing stage. In our study, the mean length of the soft palate antero-posteriorly in OSMF patients was significantly less than the corresponding value in control subjects signifying the fibrotic changes occurring leading to a shrunken uvula.

Dr. SupriyaSankpal



Dr. BIRANGANE R.S.
PRINCIPAL
P.D.U. Dental Collg - Solapur

Study was conducted on 90 study patients were divided into 3 groups:

1. Group I - 30 individuals with established OSMF group (study group 1)
2. Group II - 30 individuals with Habit only (study group 2)
3. Group III - 30 individuals with no habit and/ or OSMF group (control group)

Sample size was calculated using the formula

$$n = Z^2 pq / L^2$$

Where n = sample size

$Z_{\alpha/2}$ = point on normal distribution with 95% confidence level)

p = Prevalence

L = allowable error which is equal to 10% of p

Results: In study group-1, type-1, type-2, type-3, type-5, type-6 soft palate variant was most commonly found, of which type-6 variant has the highest percentage. In study group-2, type-1, type-2, type-3, type-5, type-6 were most commonly found which indicates that alterations in morphology of soft palate even before the development of Oral Submucous Fibrosis. In both the study groups type-4 variant of soft was not found. In control group, type-2 variant of soft palate was most commonly found.

Conclusion: The present study highlighted various morphological appearances of soft palate and comparison with habit and OSMF group on cephalogram. Cephalometry can be efficiently used to assess the morphology of soft palate and the morphology of soft palate was altered in individuals with habit even before development of OSMF. Thickness of soft palate was affected more as compared to its length. As the OSMF progresses the type of soft palate changes from type-1 to type-3 & type-6. A gradual reduction in A-P length and increase in S-I length was observed, suggesting that soft palate becomes shorter and thicker with advancing stage. In our study, the mean length of the soft palate antero-posteriorly in OSMF patients was significantly less than the corresponding value in control subjects signifying the fibrotic changes occurring leading to a shrunken uvula.

Dr. SupriyaSankpal




Dr. BIRANGANE R.S.
PRINCIPAL
D.D.U. Dental College Solapur.

(dept of oral medicine and radiology batch 2018-2021)

Evaluation of the efficacy of CBCT as compared to OPG in defining the relation of roots of the mandibular third molar with inferior alveolar nerve (IAN)

Aim:

To evaluate the efficacy of CBCT as compared to OPG in defining the relation of roots of the mandibular third molar with Inferior Alveolar Nerve.

Objectives:

To compare the reliability of CBCT over OPG in preoperative examination of relation of roots of third molar with Inferior Alveolar Nerve.

- To determine which radiographic sign on panoramic radiography indicate a true relationship on CBCT.

Material and method- Study conducted on 100 patients were selected with impacted or partially erupted third molar who had taken an OPG for the same.

Sample size was calculated using the formula:

$$n = z^2 \cdot p \cdot q / (L^2)$$

Where, n = Sample size

$z = 1.96$ (A point on normal distribution with 95% confidence level)

$$p = 57.5\%$$

$$q = 1 - p = 100 - 57.5 = 42.5\%$$

L = Allowable error which is equal to 10% of p

i) Patients with age above 18 years, with impacted/partially erupted mandibular third molar will be included in the study. Only those patients with completely formed roots of mandibular third molars. Patients who showed close relationship between third molar and mandibular canal will be evaluated on panoramic radiography. Patients who showed a risk of IAN injury, as diagnosed on digital panoramic radiographs, underwent additional; CBCT imaging.

A total 100 patients from Department of oral medicine and radiology were enrolled in the study, of which all had impacted or partially erupted third molars and who had taken OPG for the same. All the patients were then subjected to undergo CBCT for the same third molars. These patients were included in the study and were considered

Panoramic Radiograph:

CS 8000 C Carestream digital panoramic and cephalometric system, with direct digitalization was used to obtain panoramic radiograph. Cone Beam Computed Tomography (CBCT): IMorita (Fushimi-ku, Kyoto, Japan) cone beam 3D Extraoral imaging system with a reconstruction



Dr. BIRANGANE R.S.
PRINCIPAL
Dental College, Solapur.

volume of 50x37mm was used to obtain the CBCT images. The equipment has CMOS sensor technology.

Results- among all of the signs, the darkening of root apex seen maximum number of times on the OPG as 53% followed by other signs such as the interruption of white line(s) seen in 29%. Also, the narrowing of roots, deflected roots apex and island shaped apex seen in 6%, 4% and 2% respectively. However, the diversion and narrowing of inferior alveolar nerve canal seen in only 3% samples.

Conclusion

Conventional radiography remains basic imaging modality for most of the impacted teeth. CBCT determines precise tooth position to visualize impaction with in alveolar bone, inclination of impacted tooth, location relative to adjacent teeth and proximity to vital structures such as nerve canal, and cortical borders.

Dr. Aditee Ramraj Karkade

(dept of oral medicine and radiology batch 2019-22)

Oral findings among postmenopausal women

Aim: The aim of the study was to assess the prevalence of oral changes in postmenopausal women.

Materials and method:

Informed consent was obtained before proceeding with the study from all the selected study participants.

- The case group consisted of 200 postmenopausal women and the control group included 200 age-matched men.
- And they were screened from those attended the department of Oral Medicine and Radiology for routine dental complaints.
- A proforma was framed a detailed case history was recorded and the patients were asked about dry mouth, taste and halitosis , mucosal/facial pain, burning sensation and they were examined for oral changes such as ulceration, white and red lesions among others.

Results: In the present study oral symptoms were more prevalent in postmenopausal women compared to males. Mucosal pain/burning is a subjective symptom where patient complaints



Dr. BIRANGANE R.S.
PRINCIPAL
P.D.U. Dental College Solapur.

of burning sensation in the mouth. Postmenopausal women had higher prevalence (26.0%) in the present study when compared to men (3.5%). Another observation made in the research was dry mouth/xerostomia. It is a subjective symptom where patient complains of dryness in the mouth. Postmenopausal women had higher prevalence (40.5%) in the present study when compared to men (7.5%). Another observation made in this research was dysgeusia which is characterized by altered taste perception. In the present study altered taste is seen in (14.5%) postmenopausal women and (6.5%) men. In the present study facial pain is seen in 1% postmenopausal women and 0.5% men. In the present study, no red lesions were seen in either the postmenopausal females or the age-matched males. No ulcerative lesions were seen in the present study.

Conclusion: The findings of the present study concluded that oral symptoms are more prevalent in postmenopausal women when compared to age-matched male. Among postmenopausal women various oral findings can be seen in which burning mouth syndrome is the most common finding, whereas white lesions are the least common finding. Menopause is an important phase in a women's life, where oral health cannot be neglected. Thus, as oral physicians we should be aware of the various oral and general signs and symptoms which may be encountered in postmenopausal women so that timely identification and management of these conditions can limit the oral discomfort and therefore improve the quality of life of these postmenopausal women

Dr. Rashmi Rokade

(dept of oral medicine and radiology batch 2019-2022)

Assessment Of Submandibular Gland Fossa with Cone Beam Computed Tomography – A Retrospective Study

Aim: To evaluate the concavity of submandibular gland fossa on cone beam computed tomography.

Materials and methods: Total 200 CBCT scan images of patients were included in the study and were subject to analysis of posterior mandibular region for location of submandibular gland




DR. BIRANGANE R.S.
PRINCIPAL
P.D.U. Dental College Solapur.

fossa, deepest concavity of submandibular gland fossa, distance from alveolar crest to deepest concavity of submandibular fossa & distance of mental foramen from submandibular gland fossa using CS 3D imaging software 3.3.11. Study population included were included males and females with age group range of 20-75 years . Retrospective study was conducted on 200 patients with partially or completely edentulous ridges in relation to the posterior mandible.

Result: CBCT scan images with partially or completely edentulous ridges in relation to the posterior mandible were analyzed for depth of submandibular gland fossa and its distance from mental foramen and alveolar crest. The values obtained were in millimeter (mm). The total number of males and females in this study were 114 (57%) and 86 (43%) respectively . The three age groups in this study were 21-35 years, 36-50 years and 51- 70 years with total number of samples 96 (48%), 56 (28%) and 48 (24%) respectively in each group . Mean submandibular gland fossa depth was 1.4165 mm with SD of 0.6426, minimum value been 0.1 mm and maximum value been 4 mm. Mean distance of submandibular gland fossa from alveolar crest was 12.7475 mm with SD of 3.3530, minimum value been 5.8 mm and maximum value been 24.3 mm. Mean distance of submandibular gland fossa from mental foramen was 19.057 mm with SD of 5.5877, minimum value been 5.6 mm and maximum value been 30.6 mm.

Conclusion: The mean submandibular gland fossa depth was 1.4165 mm with minimum value been 0.1 mm and maximum value been 4 mm. The submandibular gland fossa depth for male was more than female. The submandibular gland fossa depth for 21 to 35 years age group was less and for 36 to 50 years and 51 to 70 years, the submandibular gland fossa depth was almost similar. Based on the results obtained from the present study, statistical significance was seen in cone beam computed tomography data obtained from the patients for submandibular gland fossa depth, the height from alveolar crest to greatest depth of submandibular fossa and the distance of submandibular gland fossa from mental foramen, varied between age groups and gender.

Keywords: submandibular gland fossa, CBCT, deepest concavity, 3d extraoral imaging system

Dr. Smita Lahane

(dept of oral medicine and radiology batch 2019-2022)

Prevalence of tobacco habits in Beedi workers of Western part of Maharashtra.

Aim: The aim of this study was to assess the prevalence of tobacco habits in Beedi workers of Western part of Maharashtra.

Materials and methods: Total 1000 of Beedi workers were included in the studies and were subjected to interview using questionnaire (about the tobacco habit, form of tobacco consumption, habit since (yrs.), frequency, duration, swallow/spit, tried to quit the habit and they were examined for oral changes such as ulceration, red and white lesions.) to know the detailed



Dr. BIRANGANE R.S.
PRINCIPAL
P.D.U. Dental College • Solapur

history of tobacco consumption. Study population were included both male and female with age ranges from 18 to 70 years.

Result: the study population included more female (99.4%) population than male (0.6%). Maximum percentage (40.5%) of the beedi workers found to be in this occupation was at the age group of 31-40 years. Among 1000 beedi workers out of which, 99.4% were non-tobacco user while 0.6% were having habit of tobacco consumption. In 0.6% the usage of tobacco was in the form of arecanut, mishri, raw tobacco chewing and gutkha were 2%, 1%, 2%, 1% since 5, 8, 15, 20 years respectively. In that we found 33.33% of them were having oral lesion in the form of tobacco pouch keratosis as all of them used to spit it and used to keep it in the oral cavity for maximum up to 5 minutes and no one tried to quit the habit. In the present study, smokeless form (100%) of tobacco was more prevalent than smoked form.

Conclusion: In the present study the prevalence of tobacco chewing habits in beedi workers are less. The reason behind that most of the worker was women as compare to male and all the men had the habit of tobacco chewing. Efforts should be made to control tobacco use by improving the number and quality of services of tobacco cessation treatment. The results of this study will definitely help these beedi workers to increase the awareness about the ill effects of tobacco chewing.

Keywords: Beedi workers, Arecanut, Mishri, Gutkha, Raw tobacco chewing, tobacco pouch keratosis.




Dr. BIRANGANE R.S.
PRINCIPAL
P.D.U. Dental College, Solapur

LIBRARY DISSERTATION

Batch 2016-2019

Dr Rashmi channe- Cone Beam Computed Tomography

Dr Abdullahkazi- Psychosomatic diseases affecting oral cavity

Batch 2017-2020

Dr. Vasundhara Bandagi-

Radiographic manifestations of systemic disease affecting jaw bones

Batch- 2018-2021

Dr. Shruti Wadne- Lasers in Dentistry

Dr. SupriyaSankpal- Forensic Odontology

Batch- 2019-2022

Dr. Aditee Karkade- Radiotherapy

Dr. Rashmi Rokade- Saliva as a Diagnostic Tool

Dr. SmitaLahane- Disorders of Tongue




Dr. BIRANGANE R.S.
PRINCIPAL
P.D.U. Dental College, Solapur.


Title: Comparative Evaluation of canal cleaning ability of different file systems: An in vitro Scanning Electron Microscope study.

Introduction: The cleaning and shaping of root canals is the key step in root canal treatment procedures. The introduction of nickel–titanium (NiTi) rotary instruments to dental practice has drastically changed the technique of root canal preparation. The three file system that is waveone, hyflex CM and SAF was used to clean and shape the canal. The purpose of this study is to compare and evaluate cleaning effectiveness of root canal preparation under scanning electron microscopy (SEM) using three different instrumentation systems : Rotary NiTi file system , Reciprocating file system and Self adjusting file system.

Material and Method: Sixty mesiobuccal roots of extracted mandibular molar teeth was included and stored in saline. The curved canals was selected for study. Angle of curvature was assessed according to criteria described by Schneider. Teeth was randomly divided into three groups. Access cavity was prepared allowing direct access to canal. Canal patency was established by placing a no.10, 15 SS hand K file through the apex and working length was determined. Straight line access was achieved for the different file system with the use of Gates Glidden drills #2 and #3. Canal preparation was done using three different file system that is Rotary hyflex CM, Reciprocating Waveone and Self Adjusting Files. The intracanal irrigant used after each file will be 3 mL of 3.0% sodium hypochlorite (NaOCl). A 1- minute 17% EDTA rinse followed by a final NaOCl rinse after the cleaning and shaping was completed. The teeth was dried with paper points. All samples was decoronated using diamond tip disc and root was longitudinally split buccolingually for evaluation under SEM to determine canal cleanliness. All teeth was analyzed with the SEM in the coronal, middle, and apical third of the canal. Debris was defined as dentin chips, pulp remnants, and particles loosely attached to the root canal wall.

Presence of debris will be evaluated using the scale of 5 scores as follows :

Score1: Clean root canal wall, only few small debris particles



Dr. BIRANGANE R.S.
PRINCIPAL
P. D. U. Suramwad, Dist. Solapur.

Score 2: Few small agglomerations of debris

Score 3: Many agglomerations of debris covering less than 50% of the root canal wall

Score 4: More than 50% of the root canal wall covered by debris

Score 5: Complete or nearly complete root canal wall covered by debris.

Result: Intergroup comparison of the mean debris score between Group I, Group II and Group III at Coronal, middle and apical levels using One-way ANOVA. This comparison showed statistically significant differences (p value). Pairwise multiple comparison of the mean debris score between Group I, Group II and Group III at Coronal, middle and apical levels using Tukey's Post hoc test. This comparison showed statistically significant differences between the group I and group III at coronal third, Group I and Group II at middle third and group I and group III and group II and group III at apical third.

Conclusion: Within the limitations of the current in vitro study, it has been concluded that None of the experimental groups tested were not able to clean the canal completely. SAF shows significantly better canal cleaning ability followed by WaveOne file system and Hyflex CM file system. In intragroup comparison there is no statistically significant difference between SAF file system and Hyflex CM file system, whereas WaveOne file system showed significant difference at coronal, middle and apical third. Further clinical investigations should be carried out to validate canal cleaning ability of SAF, WaveOne and Hyflex CM file system.



DR. J. K. SHARMA
PRINCIPAL
P.J. Dental College

Dr Preeti Vaprani

Batch :2018-2021

"EVALUATION AND COMPARISON OF ANTI-BACTERIAL EFFICIENCY OF 1% CETRIMIDE, DICLOFENAC AND CONVENTIONAL INTRACANAL MEDICAMENTS AGAINST ENTEROCOCCUS FAECALIS: AN IN VITRO STUDY"

Aim : Aim of the present in vitro study was to evaluate and compare the anti-bacterial efficiency of 1% Cetrimide and Diclofenac sodium over Conventional Intracanal Medicaments against Enterococcus faecalis.

Material and method: 150 single rooted mandibular premolars extracted due to orthodontic or periodontal reasons were decoronated and instrumented upto F3-ProTaper rotary. Apical sealing was done with cyanoacrylate. Samples were autoclaved , placed in Eppendorf tubes, and contaminated with E. faecalis for 14 days. Colony-forming unit (CFU) counts were taken before (CFU-1), and after intracanal medication (CFU-2) by paper point sampling. Test medicaments [Control group- Normal Saline Solution, Group no. 1- 1% Cetrimide Solution, Group no.2- Diclofenac sodium salt + distilled water (1:1 w/v), Group no.3- Calcium Hydroxide + distilled water (1:1 w/v), Group no.4- Cavisept gel, Group no.5- Triantibiotic Paste] were placed into root canals, temporarily sealed, and incubated (37°C; 7 days).

Result: Student's Paired 't' test, Student's Unpaired 't' test, one tailed Wilcoxon signed rank test, Mann-Whitney U statistic, One way ANOVA test were used. Within the limitations of the study, there is a significant difference between mean values of Anti-bacterial efficiency before and after use of intracanal medicament.

Conclusion: 1% cetrimide and TAP reduced significantly the viability of E. faecalis in an infected human dentine model in comparison with 2% CHX gel and calcium hydroxide paste and diclofenac.



✓
Dr. BIRANGANE R.S.
PRINCIPAL
P.D.U. Dental College, Solapur

Dr. Mahenaz Salam Inamdar

Batch: 2018-2021

Title of study: "Evaluation of Antimicrobial Efficacy of Newer Irrigating Solutions against *E. Faecalis* in Root Canals: An In-Vitro Study"

Aim: The aim of this study was to evaluate and compare the antimicrobial efficacy of 0.1% Octinidine Dihydrochloride, Superoxidized Solution, Ozonated Water, Silver Nanoparticles and Q mix in root canals against *E. faecalis*.

Materials and method: 150 extracted mandibular premolars with single canal were selected for this study. The samples were decoronated to standardize the root length to 14 mm.

The initial apical preparation was done up to #25(4%) rotary files to standardize the apical diameter of all the specimens. All the prepared specimens were sterilized and inoculated with *E. faecalis* (ATCC 29212). After confirming the bacterial contamination of the specimens, the initial microbial sampling was done.

The final apical preparation of the specimens was done up to #40(4%) rotary files, using 3ml of irrigating solutions to be tested for each file used. Depending on the irrigants to be tested, the specimens were divided into respective groups and final microbial sampling was done. Number of Colony Forming Units (viable *E. Faecalis*) per ml were obtained and compared statistically.

Results: The mean bacterial reduction was statistically significant for 0.1% Octinidine Dihydrochloride, Superoxidized Solution, Ozonated Water, Silver



Dr. BIRANGANE R.S.
PRINCIPAL
Pimpri Chinchwad Education Trust, Pimpri

Nanoparticles and Q mix, proving their good antibacterial activity against E. faecalis in root canals.

Conclusion: Within the parametric limitations of this in vitro study, it can be inferred that 0.1% Octenidine possess had the highest antimicrobial potential followed by Ozonated water, Qmix, Superoxidized Solution and Silver Nanoparticles (AgNp).




Dr. BIRANGANE R.S.
PRINCIPAL
P.N.U. Dental College, Solapur

Title of Topic:

A comparative evaluation of the staining susceptibility of different resin-based composites to turmeric, saffron & pomegranate juice – An in vitro study

Materials and Methods:

180 samples (10 mm diameter and 2 mm thickness) were fabricated from microhybrid (Group 1: GC G-Aenial), nanohybrid (Group 2: Voco Polofil NHT) and nanofilled (Group 3: 3M ESPE Filtek Z350 XT) composites with 60 samples in each group. Color of the specimens were measured according to the CIE $L^* a^* b^*$ system using VITA Easyshade spectrophotometer. After baseline color measurements, 15 specimens from each resin were immersed in different staining solutions for 72 hours: Subgroup A: artificial saliva (control), Subgroup B: turmeric solution, Subgroup C: saffron solution and Subgroup D: pomegranate juice I. Afterwards, new color measurements was performed. Color difference was determined by the difference (Δ) between the co-ordinates L^* , a^* , and b^* obtained from the specimens before and after immersion into the solutions.

Results:

Turkey's post hoc analysis showed significant color differences ($p < 0.05$) between all the test solutions in all the composite groups, except between artificial saliva and pomegranate juice where the differences were not significant ($p > 0.05$).

Significant color differences ($p < 0.05$) were observed between all the three groups when immersed in turmeric and saffron solutions. On exposure to pomegranate juice, the color difference was significant only between Group 1 (G-aenial™) and Group 3 (Filtek™ Z350 XT), whereas no significant differences ($p > 0.05$) were observed between Group 1 (G-aenial™) and Group 2 (Polofil NHT) and between Group 2 (Polofil NHT) and Group 3 (Filtek™ Z350 XT). When immersed in artificial saliva, no significant differences were observed between all the three groups.

[9:23 AM, 6/8/2022]

Conclusion:

✓ In all the tested composite materials, turmeric had the highest staining potential followed by saffron, whereas pomegranate juice exhibited the least staining potential.

✓ Among the three resin composites, G-aenial™ microhybrid composite showed highest color stability in all the experimental solutions, while Filtek™ Z350 XT had the least color stability.



Dr. BIRANGANE R.S.
PRINCIPAL
P.D.H. DENTAL COLLEGE, Solapur

Thesis abstract

Dr. Shubham Kassa

(Dept. of Conservative endodontics, Batch 2020-21)

Title: Evaluation of apical leakage in roots filled with various endodontics sealers: An *In-Vitro* Study.

Introduction: Endodontic treatment for tooth with damaged dental pulp aims both to prevent and cure apical periodontitis. Three-dimension obturation of the treated root canal with biocompatible filling materials is vital to avoid reinfection. The most common filling material is gutta percha. Along with sealer it has been displayed significantly less apical leakage.

The present study will be undertaken to compare and evaluate the apical sealing ability of bioactive glass sealer, ZOE, AH Plus, and MTA Fillapex.

Material and method: The study will include a total 75 samples and 5 groups. Each group will contain 15 samples. Central incisor with no root caries, no anatomical variations are selected in the study.

Group I : Control group.

Group II: MTA based sealer

Group III: AH Plus sealer

Group IV: Bioactive Glass based sealer

Group V: ZOE Based sealer

All tooth were prepared up to 60K file and flushed with 175% EDTA. Obturation was done using lateral condensation technique. Roots are immersed in methylene blue and depth of dye penetration was examined under stereomicroscope at 30 X microscope.

Conclusion: From the review it concludes that Ah Plus has show some amount of leakage while ZOE has shown maximum amount of leakage, Bioactive glass-based sealer showed minimum amount of leakage.




Dr. BIRANGANE R.S.
PRINCIPAL
P.D.U. Dental College, Solapur

TITLE: Comparative Evaluation of apical extrusion of intracanal bacteria following use of different instrumentation techniques: An in vitro study

INTRODUCTION : Root canal therapy is one of the main treatment option for pulpally infected teeth. The endodontic instrumentation mainly aims at disinfection and debridment of root canal. In reality root canal anatomy is unpredictable with curvatures, location of foramen, hence to clean and shape these canals require endodontic instrumentation along with different irrigation system to remove debris. The most common bacteria involved in root canal infection are gram +ve , gram- ve and anaerobics, enterococcus faecalis, fusobacterium nucleatum, propionbacterium.

E .faecalis has long been causative agent for persistant root canal intections and has also been identified with retreatment cases. These microorganism are resistant to most intracanal medicaments and are of great concern if extruded beyond the apex. This study will evaluate which file system extrude less bacteria during instrumentation and reduce chances of flare up.

MATERIALS & METHOD: Freshly extracted mandibular premolars will be collected and stored in saline. Access cavity will be done with round diamond bur, gates-glidden drill #3 used to prepare the canal orifices. Pulp chamber will be reservoir for contamination of root canals with bacterial suspension .Teeth will be mounted on bacteria collecting apparatus.The E.faecalis suspension will be prepare by adding 1ml of a pure culture of E.faecalis to brain-heart infusion broth.Root canals will be contaminate with pure culture of E. faecalis strain using sterile micropipettes after access opening.The #10 K file will be inserted into canals to measure the length. As the tip will be visible at apex. Working length considering 1mm short of file penetration length.The teeth will be mounted in glass vials and rubber stopper. A heated instrument will be used to create a hole through the center of rubber stopper.Nail varnish of two coats will be applied onto roots then teeth will be mounted onto glass vials. The vials act as container for extruding material through foramen. The rubber stopper vials will be vented with 27 gauge needle

for equalize pressure inside and outside .Then entire model sample system will be sterilized.

- The contaminated samples will be divided into 8 group.

Group 1 = Hand K file, Group 2 = Protaper Gold file system ,Group 3 = Hyflex EDM
Group 4 = ReciprocR25m, Group 5 = Neolix file system, Group 6 = Wave one, Group
= One shape ,Group 8 = Self adjusting file

All canals will be irrigated [10ml] 0.9% saline. At the end of root canal preparation.The irrigated solution will be collected from glass vials for counting the bacteria.The suspention will be inoculated on brain-heart infusion agar.Classic bacterial counting method will be used to count the colonies of bacteria and result will be analyzed using colony forming unit [CPF].

CONCLUSION: From review of literature it concludes that , Apical bacterial extrusion of intracanal bacteria for hand, rotary, reciprocating, single file, self adjusting file system are different.



Dr. BIRANGANE R.S.
PRINCIPAL
Solapur

Thesis Abstract

Dr. Pooja J. Sonwane

(Dept. of Conservative Dentistry & Endodontic Batch- 2020-21)

Title - Effect of bleaching on bonding and role of different antioxidants in reversing compromised shear bond strength using V generation bonding agent: An in vitro study


Introduction - Reduction in bond strength of composite resin to bleached enamel is seen especially when bonding is performed immediately after the bleaching process. Mechanism polymerization. For immediate reestablishment of esthetics, this delay in bonding procedure can be overcome by use of several postbleaching antioxidants.

The aim of the study is to evaluate the effect of proanthocynidin i.e. pine bark extract & super oxide dismutase using V generation bonding agent in reversal of compromised shear bond strength of composite resin to bleached enamel.

Materials & Method - Eighty eight extracted human permanent maxillary incisors will be collected & rinsed in 0.9% saline.

- Roots will be embedded in acrylic resin block so that coronal portion will be exposed.
- Individual molds of tooth-colored self-cure resin will be prepared over specimens.
- Solution of 10% pine bark extract (proanthocynidin) & 10% super oxide dismutase will be prepared.
- Labial surfaces of 66 specimens (group 2,3, & 4) will be bleached with Pola Office Plus Kit containing 37% hydrogen peroxide with four applications of 8 min each.
- A customised cylindrical metal mold of 3mm diameter & 5mm height will be fabricated & Composite resin restoration placed using customised cylindrical mold.
- For group 1, direct composite restoration will be done.
- For group 2, bleaching will be followed by etching & bonding
- For group 3, bleaching will be followed by 10% proanthocynidin therapy for 10 min, followed by etching & bonding.
- For group 4, bleaching will be followed by 10% super oxide dismutase therapy for 10 min, followed by etching & bonding.
- All specimens, after composite build up, will be stored in distilled water for 24hr.
- Shear bond strength testing will be done with Universal Testing Machine at across head speed of 1mm/min.

Conclusion - From review of literature it concludes that, bleaching reduces the bond strength & antioxidants help in reversing the compromised shear bond strength of composite resin using V generation bonding agent to bleached enamel.



Dr. BIRANGANE R.S.
PRINCIPAL
Pune

Dr. Abhay Munde

Batch: 2019-2022

Title of study : Comparative evaluation of fracture resistance of lithium disilicate and different composite endocrown: An in vitro study

Aim: To determine the fracture resistance of endocrowns made of lithium disilicate ceramic and different composite resin.

Materials and methods: 75 recently extracted, intact, non-carious mandibular molar teeth will be selected for the study. All teeth will be cleaned of deposits using an ultrasonic scaler, autoclaved and stored in saline. Storage period was not more than 5 months.

Endodontic access cavities will be prepared using a high speed airtor hand piece with round diamond bur and endo access bur. The working length was determined. all will be instrumented with rotary files. The canals will be irrigated with 3% sodium hypochloride during instrumentation. obturated with gutta percha and ZoE sealer using single cone technique.

Occlusal reduction was done about 2 mm above the cement-enamel junction. After occlusal reduction was finished, the internal cavity will be prepared inside the pulp chamber by removing the undercut areas of the pulp chamber and aligning its axial walls with an internal taper of 8° – 10° using a green diamond tapered bur with rounded end. The axial walls were prepared from the pulpal side to provide for a standardized cavity margin wall thickness (circumferential butt margin) of 2 ± 0.2 mm. The depth of the intracoronar cavity in the side pulp chamber was 4 mm, which will be measured from the internal cavity margin to the floor of the pulp chamber using a periodontal graded probe. After the endocrown preparation, the orifice of the canal was closed by light-curing resin-modified glass-ionomer cement, which filled the canals up to the level of the pulp chamber. Then, the teeth will be divided into four groups

Group I – In this group, each cavity will be restored with an endocrown made of lithium disilicate ceramic (IPS e.max CAD, Ivoclar Vivadent).

Group II – In this group, each cavity will be restored with an endocrown made up of composite milling blocks (VITA Enamic).

Group III – In this group, each cavity will be restored with an endocrown made of Solidex indirect composite (Shofu, Germany).

Group IV – In this group, each cavity will be restored with an endocrown made of indirect composite (Ivoclar, Vivadent).

Group V- Intact teeth, considered as the control group.

Before testing, each tooth will be vertically mounted in self-cured acrylic resin.

The fracture test will be carried out in a universal testing machine with a cross-head speed of 1 mm/s until fracture occurred.

Results : fracture resistance of lithium disilicate is greater than other groups

Conclusion: Within the limitations of the study, it can be inferred that, Lithium disilicate endocrowns had the higher fracture resistance as compared to other groups. Vita Enamic could have higher

fracture resistance than all groups except Group 1 that lithium disilicate. Group III (Solidex) and Group IV(Ivoclar) could have least fracture resistance among the tested group, but they didn't showed any significant difference.



L. PRINCIPAL
P.D.U. Dental College, S

Title: Comparative evaluation of remineralization potential of fluoride, amorphous calcium phosphate-casein phosphopeptide and bioactive glass containing toothpastes on enamel lesions: An *in vitro* study

Introduction: The exchange of mineral continues at the surface of enamel as long as the biofilm at the surface creates an environment favoring demineralization or remineralization. In the past decade, various remineralizing agents containing fluoride, calcium and phosphate ions in varied forms and concentrations were introduced. In a neutral environment, the hydroxyapatite of enamel is in equilibrium with saliva which is saturated with calcium and phosphate ions. White-spot lesions are the earliest macroscopic evidence of enamel caries. The purpose of this study was to evaluate the remineralization potential of fluoride, amorphous calcium phosphate casein phosphopeptide (ACP-CPP), calcium sodium phosphosilicate (CSP) and combination of NaF and novamin.

Material and method: 50 extracted premolars were collected and the radicular part of each tooth was removed. Each tooth was longitudinally sectioned mesiodistally into 2 sections using a high-speed diamond tip disc. Custom made plastic cylindrical molds were made and self-cured acrylic resin was poured on it. A varnish was applied around the exposed enamel surface leaving a window of 3 mm × 3 mm. Vickers microhardness tester was used to evaluate the microhardness. Vickers microhardness number (VHN) of 5 indentation were taken and average was considered. The surface microhardness determination was to compare and calculate the changes that would occur after induction of enamel lesions and after pH cycling. Two sections of each tooth were suspended into glass tubes containing 20 ml of demineralization solution, for 72 h, in an incubator at a temperature of 35°. After induction of enamel lesions, all the specimens were evaluated for surface microhardness measurements. Materials used for remineralization were: Fluor protector (Ivoclar, vivadent), Tooth mousse cream (GC), Shy NM, Sensodyne repair and protect. A cyclic regimen include alternative demineralization (2 h) and remineralization (21h) for 5 consecutive days. For

remineralization, synthetic saliva preparation was carried out. After pH cycling microhardness test was assessed again for all specimens.

Results: Within group comparison between Initial hardness, After demineralisation and After remineralisation of different groups was performed using One-way ANOVA. This comparison showed statistically significant differences (p value < 0.05) amongst all the groups between Initial hardness, After demineralisation and After remineralisation. Pairwise multiple comparison between the mean values of After remineralisation amongst individual groups was done using Tukey's Post hoc test. This comparison showed statistically significant differences between within all the groups; except the group 4 and 5, group 2 and 3.

Conclusion: All the four groups (SHY NM, Sensodyne repair and protect, GC Tooth Mousse, fluor protector) had higher remineralization potential than the control group as they showed higher mean remineralised area value. Although bioactive glass containing toothpastes proved to be better remineralizing agents when compared to GC Tooth Mousse and fluor protector. Bioactive glass containing toothpaste could be a better alternative as remineralizing agent.



PRINCIPAL
P.D.U. Dental College, Solapur.

Dr. snehal kamble

Batch: 2017-2019

Title of study : "COMPARATIVE EVALUATION OF SIX DIFFERENT FILE SYSTEMS FOR CANAL TRANSPORTATION, CENTERING ABILITY AND REMAINING DENTIN THICKNESS BY USING CONE-BEAM COMPUTED TOMOGRAPHY: AN IN VITRO STUDY".

Aim : Aim of the present study is to compare the canal transportation, centering ability and remaining dentin thickness by using six different file system.

Materials and methods: a total of 120 freshly extracted mandibular premolars teeth with completely formed apices will be collected (figure 1) and stored in normal saline. The presence of a single root and root canal in each tooth will be confirmed on radiographs. To get the flat reference, the crowns will be decoronated with a diamond disk (DFS, Germany) and a final dimension of 18mm length will be achieved for each tooth. Access cavities will be prepared using a high speed round carbide bur. Working length will be determined. angle of curvature will be thus determined radiographically. only teeth with a degree of curvature ranging between 10° and 24° were included in the study. A template of Self cure acrylic resin (DPI RR cold cure) will be made, in which the roots will be embedded till the cervical region so that a constant position could be obtained. All teeth will be scanned by CBCT before instrumentation. The teeth will be then randomly divided into six groups of twenty each. The 120 teeth were randomly divided into six experimental groups containing twenty teeth each namely.

GROUP-I (n=20): for Protaper Next rotary file system.

GROUP-II (n=20): for Protaper Gold Rotary file system.

GROUP-III (n=20): for 2Shape Rotary file system.

GROUP-IV (n=20): for WaveOne Gold Reciprocating file system.

GROUP-V (n=20): for HyFlex EDM Rotary file system.

GROUP-VI (n=20): for Neolix Neoniti Rotary file system.

The amount of canal transportation will be determined by measuring the shortest distance from the edge of an uninstrumented canal to the periphery of the root and then comparing this with the same measurements obtained from the instrumented image.

Evaluation of Centering Ability will be done.

Evaluation of Remaining dentin thickness will be done.

Results: it can be inferred that statistically significant difference between these file systems ($p < 0.05$) at all three levels which are 3mm, 6mm and 9mm of canal transportation, centering ability and remaining dentin thickness. Considering intragroup comparison of transportation, centering ability and remaining dentin thickness at 3, 6, 9mm there was no significant difference in values of six file systems.

Conclusion: HyFlex EDM and WaveOne Gold performed best at all three levels in the root canals with less transportation and maximum canal centering ability and remaining dentin thickness. Proaper Next showed more transportation and less centered and lowest remaining dentin thickness compared to other group.



Dr. B. B. WAGANE R.S.
PRINCIPAL
P.D.U. Dental College Solapur

Dr. Rahul Chole

Batch: 2017-2020

Title of study: " A COMPARATIVE EVALUATION OF CYCLIC FATIGUE RESISTANCE OF DIFFERENT NICKEL-TITANIUM FILE SYSTEMS : AN IN-VITRO STUDY

Aim: Aim of this in- vitro study is to compare and evaluate the cyclic fatigue resistance of different rotary and reciprocating file systems in custom made stainless steel canal.

Materials and method: This in-Vitro study was performed on One hundred and Twenty Ni-Ti Rotary and Reciprocating Instruments consisting Twenty in each group.

All the Files of 25mm length were rotated on stainless steel metal block until fracture was observed visually.

The glass slab covered the stainless steel block which allowed for visualization of the files were rotating in the canal and the removal of broken instruments between tests.

Results: The sequence from Maximum mean to minimum mean No. cycles after which visible fracture occurred is as follows: Hyflex EDM > Protaper Gold > NeoEndo Flex > Protaper Next > Wave One gold > Two shape

There was statistically significant difference in the No. cycles after which visible fracture occurred between Protaper Gold and NeoEndoFlex and it was 64.70 ($p > 0.05$).

There was statistically significant difference in the No. cycles after which visible fracture



occurred between Protaper Next and NeoEndoFlex and it was 44.85 ($p > 0.05$).

There was statistically significant difference in the No. cycles after which visible fracture occurred between Protaper Next and WaveOne Gold and it was 45.60 ($p > 0.05$).

Conclusion: The cyclic fatigue resistance of Six different file systems i.e. Protaper Next, Protaper Gold, Hyflex EDM, Waveone Gold Primary, Two Shape and Neo Endo Flex were evaluated and compared in custom made stainless steel canal. Within the limitations of this study, following conclusions were drawn:

1. Hyflex EDM has highest cyclic fatigue resistance as compared to other file systems.
2. Two shape has showed lowest cyclic fatigue resistance as compared to other file systems.
3. The highest mean length at which fracture occurred is observed with Hyflex EDM and Protaper Next i.e 5.74mm.



Dr. BIRANDINE R.S.
PRINCIPAL
P.D.U. Darbhanga * Solapur.

Dr. Priyanka Gitte

Batch: 2017-2020

Title of study: EFFECT OF DIFFERENT POST SYSTEMS ON THE FRACTURE RESISTANCE OF ENDODONTICALLY TREATED ANTERIOR TEETH: AN IN-VITRO STUDY"

Aim: Aim of this in-vitro study is to evaluate the effect of the different post system on the fracture resistance of endodontically treated anterior teeth.

Materials and method: The purpose of this in-vitro study was to evaluate and compare the mode of failure of restoration in endodontically treated teeth with six different post systems (Cast Post, Metal Post, Carbon fiber Post, Glass fiber Post, Quartz fiber post and Zirconia Post).

Step 1: Collection of extracted maxillary central incisor teeth as samples.

Step 2: Sectioning of the samples.

Step 3: Root canal treatment.

Step 4: Post space preparation and cementation of post .

Step 5: Mounting of tooth sample in acrylic resin block.

Step 6: Core build-up.

Step 7: Testing of Samples.

Result : A statistical significant difference was observed in the fracture resistance between Control group and cast post, control group and metal post, control group and carbon fiber post, control group and glass fiber post, control

group and quartz fiber post, cast post and metal post, cast post and carbon fiber post, cast post and glass fiber post, cast post and quartz fiber post, cast post and zirconia post, metal post and cast post, metal post and carbon fiber post, metal post and glass fiber post, metal post and quartz fiber post, metal post and zirconia post, carbon fiber post and glass fiber post, carbon fiber post and zirconia post, glass fiber post and zirconia post, quartz fiber post and zirconia post with $p < 0.05$.

The highest difference for fracture resistance was found between cast post and control group and the least significant difference was found between carbon fiber post and zirconia post.

No significant difference was observed between control group and zirconia post, carbon fiber post and quartz fiber post, glass fiber post and quartz fiber post indicating that they have comparable fracture resistance.

Conclusion:

- Cast post has higher fracture resistance as compared to other fibre posts.
- The mode of failure for cast post was predominantly unfavourable (Root fracture).
- All the fibre posts showed more favourable failures which were predominantly incoronal region as compared to cast posts.
- Among the fibre posts, Glass fiber posts showed highest fracture resistance.
- Among the fibre posts, Prefabricated zirconia posts showed least fracture resistance.



Dr. BIRANGANE R.S.
PRINCIPAL
P. N. J. Dental College, Solapur

Dr. Hetal Shah
Batch: 2016-2028

"COMPARATIVE EVALUATION OF COMPRESSIVE STRENGTH AND SHEAR BOND STRENGTH OF CENTION-N, RESIN-MODIFIED GLASS IONOMER CEMENT, BULK-FILL COMPOSITES AND LIGHT-CURE NANOCOMPOSITES: AN *IN VITRO* STUDY."

Aim: The aim of present in-vitro study is to comparatively evaluate the compressive strength and shear bond strength of Cention-N, Resin-modified Glass Ionomer Cement, Bulk-fill composite and Light-cure nanocomposite.

Materials and method:

A) For calculation of compressive strength- Customized cylindrical moulds of 4 mm diameter and 6 mm height were taken. 120 cylindrical specimens were prepared by placing restorative material in these moulds according to four experimental groups Cention-N, resin-modified glass ionomer cement, bulk-fill composite and light-cure nanocomposite. These restorative materials were condensed, cured with QTH light and stored in distilled water for 24 hours. The specimens were then transferred to UTM at crosshead speed of 1mm/min at 90 deg to restoration and compressive strength was calculated according to formula $CS = \text{load} / \pi r^2$.

B) For calculation of shear bond strength- 30 intact human molars were taken and prepared by sectioning the tooth into 4 parts from buccal and lingual surfaces from occlusal surface to CEJ in mesio-distal direction with straight handpiece. The parts were separated from root surface from CEJ. Each part was carefully shaped into 4×4×2mm dimension and stored in saline. The specimens were divided into 4 experimental groups of 30 each as Cention-N, resin-modified glass ionomer cement, bulk-fill composite and light-cure nanocomposite. These restorations were placed on prepared enamel slabs. Each restoration was 3mm in diameter and 2mm in thickness. The restored slabs were then mounted on acrylic moulds and specimens were prepared. The specimens were attached to UTM. A chisel with knife-edge was gently held flushing against the restorative interface and loaded at cross-head speed of 1mm/min until bond failure occurred. The load in failure was recorded in N/mm² and then converted into megapascals.

Result: ANOVA test and Tukey's Kramer Multiple Comparison post hoc test were used. Within the limitations of this study, there is statistically significant difference of mean values amongst all the tested groups for both compressive and shear bond strength.

Conclusion: Of all the four restorative materials, Cention-N has the highest compressive strength and shear bond strength whereas resin-modified glass ionomer cement has the least.



Dr. BIRANGANE R.S.
PRINCIPAL
P.D.U. Dental College, Solapur

Dr. Sumit S. Tambake

Batch: 2015-2018

**Title of study: " Evaluation of penetration of resin sealer with two different irrigation systems using confocal laser scanning microscope :
A Comparative *In VITRO STUDY*".**

Aim: The aim of this in-vitro study is to compare the two different irrigation system and evaluation of a sealer penetration into dentinal tubules.


Materials and method: 60 recently extracted human single rooted teeth are selected. All teeth will be thoroughly cleaned and washed and will be then stored in thymol solution until further use.

METHODOLOGY:

60 recently extracted human single rooted teeth are selected. All teeth will be thoroughly cleaned and washed and will be then stored in thymol solution until further use.

PREPARATION: Access cavity is prepared with 4 surrounding walls and then working length will be established radiographically. Root ends of all teeth will be dried and sealed with glue to simulate in vivo condition.¹

Teeth will be randomly divided into three groups (n=20) according to the irrigation technique used.



Two different Groups:

Group A: Instrumentation with protaper file and conventional needle irrigation delivery system.

Group B: Instrumentation with protaper file and EndoVAC irrigation system.

Group C: Instrumentation with protaper file and sonic irrigation system.

Group A to Group C will be instrumented with protaper file up to F3 using 5% NaOCl irrigation between each instrumentation. Then each sample will be subjected to irrigation with 10 ml of 17% EDTA.

All the canals will be dried with absorbent paper points, obturated with AH Plus sealer and single cone obturation technique using gutta percha. For fluorescence under confocal laser microscope sealer will be mixed with 0.1% rhodamine B isothiocyanate.¹ The obturation will be assessed radiographically.

After the sealer had completely set, each tooth will be sectioned perpendicular to its long axis in 1mm thick sections at points 2 and 6 mm from root apex and all specimens will be mounted on to glass slide to observe under confocal laser microscope.¹

The method use to evaluate is given by Gharib et al.¹


1. Each sample image will be imported into Photoshop (Adobe system).
2. In each sample image, the circumference of root canal wall will be outlined and measured with Photoshop measuring tool.
3. Next areas along the canals walls in which the sealer penetrated into dentinal tubules will be outlined and measuring will be done using same method.

4. The outlined lengths where sealer had penetrated were divided by canal circumferences to calculate the percentage of sealer penetration into canal wall.

Results: To determine statistical difference for the depth of penetration and percentage of sealer by using conventional, sonic, ultrasonic and EndoVac irrigation system at apical middle . The data was complied using Microsoft Excel Spreadsheet and subjected to statistical analysis using statistical package of social science (SPSS) version 16.

Conclusion: In our present study, none of the activation/delivery system completely removed smear layer from endodontic dentin walls and had full penetration and percentage of sealer penetration into dentinal tubules. Nevertheless, EndoVac irrigation system showed best result at 2mm and 6mm level from apex.




Dr. BHANU R.S.
PRINCIPAL
P.D.U. Dental College, Solapur.

Dr. Kiran Maske

Batch: 2015-2018

Title of study: "EFFECT OF DIFFERENT DIETARY SOLVENTS ON THE STRENGTH OF NANOCOMPOSITE, COMPOMER AND RESTORATIVE GLASS IONOMER CEMENT "-AN IN-VITRO STUDY.

Aim: "To study the effect of different dietary solvents on the strength of Nanocomposite, Compomer and Restorative Glass Ionomer Cement"

Materials and method: The study comprised of a total of one hundred eighty samples divided in four groups pertaining to three different materials used. The dental materials used were nanocomposite , Compomer and restorative glass ionomer cement. These materials were procured directly from the market. Each material was having a manufacturer and date of expiry printed on it.

Group	Material type	Manufacturer	Date of expiry
I	Nanocomposite	Nexbio, Korea	2017-19

II	Compomer	Densply(Dyract flow), Germany	2017-19
III	Glass Ionomer Cement	GC. Japan, Tokyo	2016-19

SPECIMEN PREPARATION

One hundred eighty samples, sixty for each material were prepared as rectangular block of (10mm×5mm×5mm each) at room temperature using customised metal mould according to manufacturer's instructions. Glass slides were placed at the bottom of metal tray to produce a smooth surface. Excess material was removed by using another glass slab on top of the mould.

For the resin based restorative materials, all samples were light cured for 20 seconds from each surface of mould using a LED curing unit. For GICs, the glass powder mixture of each specimen was prepared according to manufacturer's instructions. Immediately after mixing, the cement was



inserted into the mould and its top and bottom surfaces were covered by glass slides.

Results: The mean shear strength values obtained were subjected to following statistical analysis: Descriptive statistics such as mean and SD was used. Comparison between more than two groups was done by using ANOVA test followed by post hoc Tukey Kramer Multiple Comparisons Test. A p-value less than 0.05 were considered as significant. Data analysis was performed by using software SPSS 16.0.

Conclusion:

Out of three restorative materials nanocomposite showed highest shear strength followed by compomer and restorative glass ionomer cement.

There is least significant difference between shear strength of nanocomposite and compomer.




Dr. BIRANGANE R.S.
PRINCIPAL
P.D.U. Dental College, Solapur.

ORTHO

DEPARTMENT OF ORTHODONTICS, PDUDC, SOLAPUR
POST GRADUATE STUDENTS THESIS ABSTRACTS

Dr. Salman S. Shaikh

TITLE: "Comparison of shear bond strength and adhesive remnant index of two step adhesive versus traditional cid-etched adhesive- an invitro study."

Aim: To compare the shear bond strength of colour changing adhesive along with self-etching primer with conventional adhesive technique.

Method: The study was carried on 100 extracted premolars which were extracted for orthodontic treatment purpose. The teeth were divided into 2 groups of 50 each, where one group was bonded with conventional adhesive and the other with self etching primer and with a universal testing machine. The shear bond strength of adhesives in both groups was checked viewed under atomic force microscope. The enamel surface topography around bracket area was statistical evaluation

Results: Group 1 gave rise to statistically significant high shear bond strength as compared to group 2

Conclusion: All the adhesives used in this study can be used for bonding in orthodontics as they have optimum bond strength. Among the study groups Transbond XT has higher bond strength as compared to TransbondTM Plus and SEP

Dr. Deval M. Choukhe

TITLE: "Evaluation and comparison of color stability of esthetic archwires: an in vivo study under spectrophotometer"

Aim: To evaluate and compare the color stability of three coatings of esthetic archwires.

Method: 90 patients were divided into three groups and received nickel titanium coated aesthetic round archwires with Epoxy coating, Teflon coating and ceramic coating. After three weeks, the wires were examined for colour assessment under a spectrophotometer

Results: statistically significant difference exists between the ΔE values of all groups with more alteration in Teflon group followed by ceramic coating and epoxy coating, respectively.

Conclusion: All the esthetic archwires assessed showed noticeable color change after 21 days. The JJ orthodontics archwire of the Teflon group showed the highest amount of color alteration whereas the rabbit force archwire of the Epoxy group presented least amount of color change, making it the best available archwire amongst the ones used in the study.



Dr. Birangane R.S.
DR. BIRANGANE R.S.
PRINCIPAL
P.D.U. Dental College, Solapur

Dr. Kalyani S. Chatla

TITLE: Release of nickel and chromium ions from orthodontic archwires following the use of four different mouthwashes – An In Vitro Study.

Aim: To assess the release of nickel and chromium ions from nickel titanium (NiTi) and stainless steel (SS) orthodontic wires following the use of four common mouthwashes available on the market.

Method: Release of nickel and chromium ions from 200 0.016x0.022 inch rectangular Nickel-Titanium and Stainless steel archwires immersed in different four mouthwashes was evaluated. Each group contains 40 samples. Sample size of 5 each will be assessed at four time-points. The samples will be incubated at 37°C for 1h, 6h, 12h and 1 week. Calibration will be done by measuring the amount of nickel and chromium released using Atomic Absorption Spectrometer.

Results: Increase in nickel and chromium ion release from stainless steel and nickel titanium archwires when subjected to mouthrinses. The highest release of nickel and chromium ions was in group IV (Amflor) and the least release was in group I (Himalaya). Nickel ion was released more in NiTi wires whereas Chromium ion release was more in SS wires.

Conclusion: All the mouthwashes release nickel and chromium ions within normal limits. Amflor mouthwash (Group IV) showed highest amount of ion release whereas Himalaya mouthwash (Group I) showed lowest amount of ion release.

Dr. Neha D. Deshmukh

TITLE: “Collaborative effect of wire bending and salivary pH on surface and mechanical properties of orthodontic stainless steel archwires- an in vitro study.”

Aim: To investigate the corrosive action on clinically relevant bent stainless steel archwires comparing them with the as-received straight wires in varying salivary pH solution.

Method: 160 Rectangular stainless steel orthodontic archwires sized 0.017 x 0.025 inches were cut and 80 wires were used as it is, 80 wires were bent into an ovoid archform using arch forming turret. These archwires were divided into 4 groups including both straight and bent wires and were immersed in artificial saliva with acidic, neutral and alkaline pH and distilled water as control. Surface Roughness Test using Calibrated Contact Profilometer and Flexural Test using a Universal Testing Machine were performed. The obtained data was statistically analysed.

Results: Mean surface roughness values for all curved wires in every group were more as compared to the straight wires. The highest level of surface roughness was seen with curved wires from Group I and the lowest amount was seen with straight wires from Group IV.

Conclusion: Bending of a straight wire into an archform can have significant influence on surface roughness and mechanical properties of rectangular stainless steel wires. Salivary pH value has a significant effect on mechanical properties of stainless steel wires. Salivary pH plays a collaborative role along with wire bending in affecting both surface roughness and mechanical properties of stainless steel wires.



Dr. BIRANGANE R.S.
PRINCIPAL
P.D.U. Dental College, Solapur

Dr Parul Agarwal

TITLE: Evaluating the reliability of calcification stages of maxillary canine and mandibular second molar for skeletal maturation assessment in South western Maharashtrian population - An in-vitro study.

Aim:- To evaluate whether the calcification stages of maxillary canine and mandibular second molar can be used for assessment of skeletal maturity and growth phase. To compare between maxillary canine and mandibular second molar as a more reliable indicator of skeletal maturity.

Method: The study will be conducted on Pre-treatment digital panoramic and lateral cephalometric radiographs of individuals visiting the Department of Orthodontics and Dentofacial Orthopaedics in colleges of South western Maharashtrian region. The study will include 400 samples. For dental maturation evaluation, calcification stages of permanent maxillary canine and mandibular second molar will be assessed by eight stages of calcification (A to H), assigned to the tooth as per the index described by Demirjian et al¹⁻². Cervical vertebral maturation (CVMI analysis) will be evaluated by classifying cervical vertebrae C2, C3, and C4 into six stages depending on maturation patterns depicted on the lateral cephalogram using the classification system of Hassel and Farman¹⁻². Dental and skeletal age of each patient will be determined using standardized panoramic radiographs and lateral cephalograms by trained observer. Data will be collected, tabulated, formulated and analyzed by using appropriate statistical tools.

Dr. Vaishnavi Gadhave

TITLE: Comparison of Nickel and Chromium concentration in saliva of patients before and after insertion of fixed orthodontic appliances.

Aim:- To determine whether there is significant increase in salivary level of Nickel and Chromium in patients having fixed orthodontic appliances and evaluate their different concentration at different intervals of time.

Method: Four samples of stimulated saliva will be collected from each orthodontic patient at the following times: before insertion of the fixed appliance, 1 month after insertion of the appliance, 3 months after insertion of the appliance, and 6 months after insertion of the appliance. The patients will initially rinse their mouths thoroughly with a mouthful of distilled water. After mouth rinsing, the patient will use a piece of paraffin as a chewing gum for stimulation of the salivary secretion. The patient will collect approximately 10 mL of saliva into test tube. The samples will be stored at -20° before they get processed. The use of an Atomic Absorption Spectrophotometer permits the analysis of metals in biological samples without any separation of the metal from its biological matrix. By using the spectrophotometric method, there is no necessity for extraction procedures to analyze the elements. Dilute each 0.5 mL of saliva samples to 10 ml. The samples will be analyzed with an atomic absorption spectrophotometer and the Nickel and Chromium concentrations present will be calculated.




DR. DIVYASHREE R.S.
PRINCIPAL
P.D.U. Dental College, Solapur

Ortho

Dr. Salman Shiakh

Poster presentation	Handy Orthodontics In 2019
Paper presentation	Comparative Assessment between Maxillary and Mandibular Apical base Length with Severity of Dental Crowding and Spacing in Class II Malocclusion Cases in South-Western Maharashtra In 2020
LD Topic	Retraction mechanics and its recent advances.
Thesis Topic	Comparision of shear bond strength and adhesive remenant index of two step versus traditional acid etched adhesive- an in vitro study
Publication	<p>1) AN ANTIOXIDANT LYCOPNE EFFECTIVE IN OSMF- AN INVIVO STUDY, World Journal of Pharmaceutical Research SJIF Impact Factor 8.084 Volume 10, Issue 4, 1006-1011</p> <p>2) Evaluation of Thickness of Buccal Attached Gingiva at Common Miniscrew Insertion Sites in Orthodontic Patients with Different Facial Types, JMSCR Vol 09 Issue 03 Page 215-223 March</p> <p>3) Comparative Assessment between Maxillary and Mandibular Apical base Length with Severity of Dental Crowding and Spacing in Class II Malocclusion Cases in South-Western Maharashtra Population, International Journal of Contemporary Medical Research, Volume 8 Issue 5 May 2021 </p>




Dr. BIRANGANE R.S.
PRINCIPAL
P.D.U. Dental College, Solapur

Dr. Deval choukhe

presentation	CAN CELLPHONE REPLACE DSLR CAMERA ? IS IT TIME TO SWITCH? IN 2019
presentation	Evaluation of thickness of buccal attached gingiva at common miniscrew insertion sites orthodontic patients with different facial types: A Comparative study In 2020
Topic	Orthognathic surgery
Topic	EVALUATION AND COMPARISON OF COLOR STABILITY OF ESTHETIC ARCHWIRES: AN IN VIVO STUDY UNDER SPECTROPHOTOMETER"
Publication	1)AN ANTIOXIDANT LYCOPNE EFFECTIVE IN OSMF- AN INVIVO STUDY, World Journal of Pharmaceutical Research SJIF Impact Factor 8.084 Volume 10, Issue 4, 1006-10112 2)Evaluation of Thickness of Buccal Attached Gingiva at Common Miniscrew Insertion Sites in Orthodontic Patients with Different Facial Types, JMSCR Vol 09 Issue 03 Page 215-223 March8 Issue 5 May 2021 3)Comparative Assessment between Maxillary and Mandibular Apical base Length with Severity of Dental Crowding and Spacing in Class II Malocclusion Cases in South-Wester Maharashtrian Population, International Journal of Contemporary Medical Research, Volume 8 Issue 5 May 2021



Dr. BIRANGANE R.S.
PRINCIPAL
P.D.U. Solapur
Solapur

Dr. Neha Deshmukh

presentation

- 1) Surgery First Approach
Presented in IOS convention 2019
- 2) Accelerated Orthodontics
Presented in ORMCO APAC 2020

presentation

- 1) Precision of CVM I in assessing skeletal maturity of post pubertal population in solapur city presented in orthobyte2020

Topic

Topic

Collaborative effect of wire bending and salivary pH on surface and mechanical properties of orthodontic stainless steel archwires- an in vitro study

presentation

- 1) Precision of CVM I in assessing skeletal maturity between class 2 and class 3 postpubertal Indian population: a comparative and cross sectional study.
(Under review for publication)
- 2) Correlation of cephalometric and photographic measurements in different skeletal patterns (Under review for publication)

Dr. Kalyani Chatla

presentation

- 1) SMILE - A POWERFUL MEDICINE
24th Indian Orthodontic Society 2020.
- 2) Molar distalizers presented in Ormco APAC E- poster contest
30 Aug 2020

presentation

Evaluation Of Pharyngeal Airway Space And Hyoid Bone Position In Different Skeletal Patterns: A Radiographic Study.
Orthobyte 202

Topic

Topic

Skeletal Anchorage System In orthodontics

Release of nickel and chromium ions from orthodontic archwires following the use of four different mouthwashes-An In Vitro Study.

presentation

1) Evaluation Of Pharyngeal Airway Space And Hyoid Bone Position In Different Skeletal Patterns: A Radiographic Study

2) COLOUR STABILITY OF ORTHODONTIC ESTHETIC ELASTOMERIC LIGATURES - AN IN VIVO STUDY



Dr. BIRANGANE R.S.
PRINCIPAL
P.D.U. Dental College, Solapur

Dr. Parul Agarwal

Poster presentation	Orthodontics, let's think face 55 TH IOS Conference 2021
Paper presentation	
LD Topic	Recent advances in diagnosis in Orthodontics
Thesis Topic	Evaluating the reliability of calcification stages of maxillary canine and mandibular second molar for skeletal maturation assessment in South western Maharashtrian population - An in-vitro study.
Publication	

Dr. Vaishnavi Gadhave

Poster presentation	LIFE AFTER ORTHODONTIC TREATMENT 55 TH IOS Conference 2021
Paper presentation	-
LD Topic	Biomechanics in Orthodontics
Thesis Topic	Comparison of Nickel and Chromium concentration in saliva of patients before and after insertion of fixed orthodontic appliances. An in vivo study
Publication	-



Dr. BIRANGANE R.S.
PRINCIPAL
P.D.U. Dental College, Solapur.

Dr. Madhura Wagh

Poster presentation	stereophotogrammetry- a 3D facial photography in IOS workshop 2022 (3 rd PRIZE)
Paper presentation	
LD Topic	
Thesis Topic	A comparision of reliability of cephalometric measurments obtained from three digital cephalometric softwares- AutoCEPH, OneCeph and WebCeph with the conventional method.
Publication	

Dr. Phalguni Warate

Poster presentation	Nano Robotics – Boon to orthodontics
Paper presentation	
LD Topic	
Thesis Topic	Evaluation of different modes of diode laser irradiation at debonding of ceramic and resin brackets ,and its comparision with conventional debonding method using debonding instruments on extracted premolar- an in vitro study
Publication	



Dr. BIRANGANE R.S.
PRINCIPAL
P.D.U. Dental College Solapur